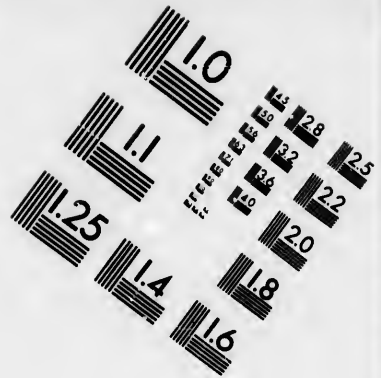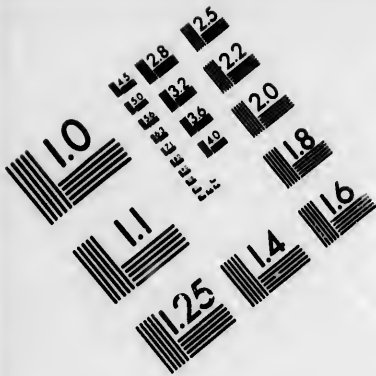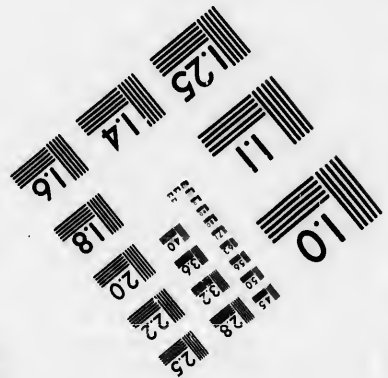





**IMAGE EVALUATION
TEST TARGET (MT-3)**



**Photographic
Sciences
Corporation**

23 WEST MAIN STREET
WEBSTER, N.Y. 14580
(716) 872-4503

15 28 25
13 19 22
16 20 18

**CIHM/ICMH
Microfiche
Series.**

**CIHM/ICMH
Collection de
microfiches.**



Canadian Institute for Historical Microreproductions / Institut canadien de microreproductions historiques

11 10
87 57

© 1986

Technical and Bibliographic Notes/Notas techniques et bibliographiques

The institute has attempted to obtain the best original copy available for filming. Features of this copy which may be bibliographically unique, which may alter any of the images in the reproduction, or which may significantly change the usual method of filming, are checked below.

L'Institut a microfilmé la meilleure exemplaire qu'il lui a été possible de se procurer. Les détails de cet exemplaire qui sont peut-être uniques du point de vue bibliographique, qui peuvent modifier une image reproduite, ou qui peuvent exiger une modification dans la méthode normale de filmage sont indiqués ci-dessous.

- Coloured covers/
Couverture de couleur
- Covers damaged/
Couverture endommagée
- Covers restored and/or laminated/
Couverture restaurée et/ou pelliculée
- Cover title missing/
Le titre de couverture manqua
- Coloured maps/
Cartes géographiques au couleur
- Coloured ink (i.e. other than blue or black)/
Encre de couleur (i.e. autre que bleue ou noire)
- Coloured plates and/or illustrations/
Planches et/ou illustrations au couleur
- Bound with other material/
Relié avec d'autres documents
- Tight binding may cause shadows or distortion along interior margin/
La reliure serrée peut causer de l'ombre ou de la distorsion le long de la marge intérieure
- Blank leaves added during restoration may appear within the text. Whenever possible, these have been omitted from filming/
Il se peut que certaines pages blanches ajoutées lors d'une restauration apparaissent dans le texte, mais, lorsque cela était possible, ces pages n'ont pas été filmées.
- Additional comments:/
Commentaires supplémentaires:

- Coloured pages/
Pages de couleur
- Pages damaged/
Pages endommagées
- Pages restored and/or laminated/
Pages restaurées et/ou pelliculées
- Pages discoloured, stained or foxed/
Pages décolorées, tachetées ou piquées
- Pages detached/
Pages détachées
- Showthrough/
Transparence
- Quality of print varies/
Qualité inégale de l'impression
- Includes supplementary material/
Comprend du matériel supplémentaire
- Only edition available/
Seule édition disponible
- Pages wholly or partially obscured by errata slips, tissues, etc., have been refilmed to ensure the best possible image/
Les pages totalement ou partiellement obscurcies par un feuillet d'errata, une pelure, etc., ont été filmées à nouveau de façon à obtenir la meilleure image possible.

This item is filmed at the reduction ratio checked below/
Ce document est filmé au taux de réduction indiqué ci-dessous.

10X	14X	18X	22X	26X	30X
<input type="checkbox"/>	<input type="checkbox"/>	<input type="checkbox"/>	<input checked="" type="checkbox"/>	<input type="checkbox"/>	<input type="checkbox"/>
12X	16X	20X	24X	28X	32X

The copy filmed here has been reproduced thanks to the generosity of:


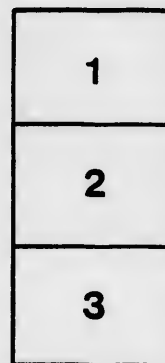

Medical Library
McGill University
Montreal

The images appearing here are the best quality possible considering the condition and legibility of the original copy and in keeping with the filming contract specifications.

Original copies in printed paper covers are filmed beginning with the front cover and ending on the last page with a printed or illustrated impression, or the back cover when appropriate. All other original copies are filmed beginning on the first page with a printed or illustrated impression, and ending on the last page with a printed or illustrated impression.

The last recorded frame on each microfiche shall contain the symbol \rightarrow (meaning "CONTINUED"), or the symbol ∇ (meaning "END"), whichever applies.

Maps, plates, charts, etc., may be filmed at different reduction ratios. Those too large to be entirely included in one exposure are filmed beginning in the upper left hand corner, left to right and top to bottom, as many frames as required. The following diagram illustrates the method:



L'exemplaire filmé fut reproduit grâce à la générosité de:

Medical Library
McGill University
Montreal

Les images suivantes ont été reproduites avec le plus grand soin, compte tenu de la condition et de la netteté de l'exemplaire filmé, et en conformité avec les conditions du contrat de filmage.

Les exemplaires originaux dont la couverture en papier est imprimée sont filmés en commençant par le premier plat et en terminant soit par la dernière page qui comporte une empreinte d'impression ou d'illustration, soit par le second plat, selon le cas. Tous les autres exemplaires originaux sont filmés en commençant par la première page qui comporte une empreinte d'impression ou d'illustration et en terminant par la dernière page qui comporte une telle empreinte.

Un des symboles suivants apparaîtra sur la dernière image de chaque microfiche, selon le cas: le symbole \rightarrow signifie "A SUIVRE", le symbole ∇ signifie "FIN".

Les cartes, planches, tableaux, etc., peuvent être filmés à des taux de réduction différents. Lorsque le document est trop grand pour être reproduit en un seul cliché, il est filmé à partir de l'angle supérieur gauche, de gauche à droite, et de haut en bas, en prenant le nombre d'images nécessaire. Les diagrammes suivants illustrent la méthode.

LABORATORY
OF THE
DEPARTMENT OF THE INSTITUTES OF MEDICINE,
MCGILL COLLEGE.

The following Practical Courses may be taken by Students :—

- I. PRACTICAL PHYSIOLOGY, including practical exercises in Physiological Chemistry and a series of demonstrations, with apparatus, illustrating important physiological laws.

Winter Session—Saturdays, 2-4 P.M.

- II. NORMAL HISTOLOGY.—The examination and preparation of the healthy tissues. Microscopes and reagents provided.

Winter Session—Bi-weekly.

- III. MORBID ANATOMY.—A series of demonstrations on the coarse (macroscopic) appearance of organs and tissues in a diseased state.

Winter Session—Saturdays, 10 A.M.

- IV. CLINICAL MICROSCOPY.—A course specially designed to meet the requirements of the practitioner, including examination of sputa, urine, blood in disease, tumours, &c.

Summer Session—Bi-weekly.

WILLIAM OSLER, M.D., *Professor.*

T. WESLEY MILLS, M.A., M.D., *Assistant.*

DEPARTMENT OF INSTITUTES OF MEDICINE MCGILL COLLEGE.

STUDENTS' NOTES.

I.

NORMAL HISTOLOGY

FOR

LABORATORY AND CLASS USE.

BY

WM. OSLER, M.D.,

MEMBER OF THE ROYAL COLLEGE OF PHYSICIANS, LONDON; FELLOW OF THE
ROYAL MICROSCOPICAL SOCIETY, LONDON; PROFESSOR OF THE INSTI-
TUTES OF MEDICINE MCGILL UNIVERSITY; PHYSICIAN AND
PATHOLOGIST TO THE GENERAL HOSPITAL, MONTREAL.

MONTREAL:

DAWSON BROTHERS, PUBLISHERS.

1882.

TO THE STUDENT.

A practical course on Normal Histology is advantageous in many ways: it affords you a practical acquaintance with the appearance and modes of preparation of tissues in health; it familiarizes you with the use of the Microscope, and it assists in the formation of those habits of accurate observation which should form an important part of your training. Keep in mind, from the outset, that you are not to become Histologists, but Practitioners; so regard this course as one among many means to the end which should be ever before you, viz., proficiency in the diagnosis and treatment of disease. Once in active practice, and not a day will pass without an opportunity of using the Microscope to assist in the diagnosis of obscure affections. It is of equal importance with the Stethoscope, the Ophthalmoscope and the Laryngoscope, and ignorant of its teachings you cannot practice with due credit to yourself, or with full justice to your patients. To become expert in its use requires time and patience—not more time, however, than, with judicious economy, the hard-worked student can well afford, and not more patience than should “possess the soul” of any one who aspires to such a profession as medicine.

These Notes will also be, I hope, of use in the lecture-room and in the weekly Demonstrations on Histology. For fuller details in microscopic technology the student is referred to the manuals of Schäfer, Rutherford and Stirling; for additional information on the structure of tissues, to the works of Klein, Ranvier, Frey, Stricker, Satterthwaite and others, which are accessible in the Laboratory.



INTRODUCTION.

THE MICROSCOPE. The most essential requisite in histological work is a good microscope, of a magnifying power of at least 300 diameters. The instrument which I prefer, and which is used in the Laboratory, McGill College, is the III. A. of Hartnack (now Prazmowski), 1 Rue Bonaparte, Paris; it costs about \$40. Other microscopes which I can recommend are Swift's (University street, Tottenham Court Road, London), and Parkes'* (Birmingham); Pillischer, of Bond street, London; Zeiss, of Jena; and Véric, of Paris.

The *stand* should be firm and solid; the horse-shoe of the Hartnack model is steadier, I think, than the tripod.

The *stage* should be plain, without other accessories than a pair of clips to hold the glass slip when the pillar of the instrument is bent at an angle. Moveable stages of all kinds are unnecessary, and are greatly inferior to the fingers when once properly educated by practice.

The *pillar* of the instrument is usually provided with a hinge, but for the greater portion of the work of an histology class the stage must be kept level.

The optical part of the instrument consists of the *lens* or *objective* and the *eye-piece* or *ocular*. The lenses of foreign makers are distinguished by numbers, 1, 2, &c.; those of English makers by their focal length, $\frac{1}{2}$ -inch, $\frac{1}{4}$ -inch, &c. With Hartnack's III. A., Nos. 4 and 7, with Swift's or Parkes' a 1-inch and a $\frac{1}{6}$ th, are provided, and are designated respectively the high and low powers. The No. 7 or the $\frac{1}{6}$ th is a high enough power for the ordinary purposes of a medical student or practitioner. For special studies, when higher powers are required, the No. 9 or

* Messrs. Frothingham & Workman, St. Paul street, Montreal, keep a supply of this maker's instruments. I have recommended them to a number of medical men, to whom they have given great satisfaction.

11 *immersion* of Hartnack or the F. of Zeiss may be used. An *immersion* lens is one in which a minute drop of water, oil or glycerine is placed between the lens and the top cover. The sharpness of definition and the illumination is thereby increased.

The *eye-pieces*, of which two are usually provided, are numbered 1, 2, 3, &c., in the foreign instruments, and A., B., &c., in those of English makers. The shorter the eye-piece, the higher the magnifying power. Nos. 3 and 4 are usually provided with Hartnack's III. A., and A. and B. with the English instruments. When using a *high* objective it is best to have a *low* eye-piece. The No. 7 Hartnack goes, in ordinary use, with the No. 3 eye-piece, and gives a magnifying power of about 300 diameters.

The *adjustments*, two in number, the *coarse* and *fine*, are the means by which the focus is obtained. The former is effected by pushing down the tube which bears the ocular and objective until it approximates the slide. This should be done carefully, with a *screw-like motion*, otherwise the tube is apt to go down too fast. The brass must be kept quite bright, else the motion is hard and jerky. In larger instruments this is effected by means of a rack and pinion. When the objective is brought to within a short distance of the slide, the fine adjustment is used. This is usually in the form of a milled-head screw at the upper part of the supporting pillar of the microscope, by the rotation of which the horizontal piece bearing the tube is slowly elevated or depressed.

Illumination. By a *mirror* under the stage in the case of transparent objects, and by a *bull's-eye condenser* in opaque specimens. The mirror is usually a little concave, and the light is best reflected from the blue sky or a white cloud; never direct sunlight. For artificial illumination, an ordinary lamp with a good flame will suffice; a whiter light is obtained by using a light-blue chimney-glass. A *diaphragm* is placed under the stage, with apertures of various sizes, by which the amount of light can be regulated. It is well to examine objects with different degrees of illumination. With high powers use one of the smaller apertures.

The following details are to be followed in examining an object, as a drop of milk:—See that the glass slip and

the top-cover are quite clean ; place the drop in the centre of the former, and with the finger or forceps apply one edge of the top-cover to the margin of the drop, and let it down slowly, so as to avoid enclosing air-bubbles. See that the quantity is only just enough to fill the space between the top-cover and the slide ; any superfluous fluid is to be absorbed by blotting-paper. Place the slide on the stage, being careful to lift up the tube, so as to get the objective out of the way. Arrange the mirror for illumination, a little manipulation being necessary to get the light properly reflected through the diaphragm. Then gently rotate the coarse adjustment until the faint outline of the object on the slide can be seen, and with the fine adjustment bring it clearly into view, or focus. Where there is only a small quantity of material on the slide, it is perhaps better for beginners to push the tube down until the objective (No. 7) is about $\frac{1}{6}$ th of an inch from the top-cover, and then use the fine adjustment. In the examination of specimens it is well to get into the habit of grasping the edges of the slide firmly with the forefinger and thumb of the left hand, and with those of the right the milled-head fine adjustment. By this means the various parts of the slide can be rapidly brought into view, and the focus quickly altered. In removing the slide *always* lift the tube up.

Drawing. It is of paramount importance for the student to learn to draw the various objects he sees, and for this purpose he should provide himself with a sketch-book and an H. B. and 4 H pencils. The rule is, *draw the object just as it looks*. The *camera lucida* may be employed to ensure greater accuracy.

For the theory of the Microscope, consult Rutherford's Manual ; for description of various microscopical accessories, Carpenter's Text-book and the Histological part of Sanderson's Hand-book for the Laboratory.

PREPARATION OF TISSUES.

Indifferent fluids. It is a good rule always to examine specimens in a fresh state. For this purpose certain reagents are used, which do not alter materially the appearance of the tissues, and are called indifferent fluids. The chief of these are solution of common salt, $\frac{3}{4}$ %,—the most useful and generally employed ; blood serum, or aqueous humor from eyes of sheep or ox, and blood serum with a few drops of iodine—iodized serum.

Teasing. Fresh specimens are usually examined after the process of *teasing*, an art of some delicacy and rarely well learned by the student. Take a *small* bit of the tissue, and place it on a slide with a *small* drop of salt solution or serum ; with one needle fix it, and with the other tease away a small fragment, and repeat this process until the portion is separated into minute parts. In the case of a fibrous tissue separate the elements, as far as possible, in the direction of the fibres. For transparent objects tease on a dark background ; for stained specimens place a piece of white paper beneath the slide. With a small drop of fluid the bits can be more readily manipulated, and then, if required, more can be added before mounting.

HARDENING. Most tissues require to go through a process of hardening, in order to render them firm enough to cut thin sections. Two methods are employed :—

(1.) *Freezing.* Applicable to most tissues, and a very speedy and convenient way. During the winter months in this country it is only necessary to expose an organ to the air for a few hours, or place it over night between the double windows, and it freezes hard enough to cut sections with a cold razor. One of the many forms of freezing microtomes serves the same purpose, and has the advantage of being always available.

(2.) Various hardening fluids, the chief of which are :

Bichromate of potash, 2% solution, 20 grms. in 2,000 c.c. of water. Solution should be changed every three or four days. Hardens tissues in about three weeks.

Müller's fluid. Bichromate of potash, 25 grms. ; sulphate of soda, 10 grms. ; water, 2,000 c.c. A most useful fluid ; alters the tissues very slightly ; hardens slowly, and does not require to be changed so often.

Chromic acid, $\frac{1}{4}$ to $\frac{1}{6}$ % solutions. It is best to make a one per cent. solution, 10 grms in 1,000 c.c. of water, and dilute this as required. It makes the tissues more brittle than the bichromate or Müller's solutions.

With these the rule is to put small bits of the tissue at first into small quantity of the solution for a day, and then into a large amount. Changing the fluid every fourth or fifth day is often enough, and in from two to three weeks the hardening should be complete. The bits are then transferred to alcohol, in which they can be kept until needed. After taking the bits out of the above fluids it is well to let them soak in water for an hour or so to remove the superfluous solution.

Chromic acid and spirit. Chromic acid $\frac{1}{6}$ %, 1 part ; methylated spirit, 2 parts. This fluid hardens more rapidly, in from six to ten days, and is very generally employed for the solid organs.

Bichromate of ammonia, 2% solution. Useful for brain and cord.

Ammonium chromate, 5% solution. Hardens quickly, and is specially used for the kidney to show Heidenhain's rods in the cells, and also for demonstrating the inter-cellular net-work in cells.

Alcohol. The ordinary methylated spirits obtained here can be used, but absolute alcohol is better. It is well to put tissues in dilute alcohol first, and then in stronger solution, and finally in absolute alcohol. Some tissues, as mucosa of stomach, pancreas and salivary glands may be put in the strong alcohol at once ; but for most organs a preliminary hardening in Müller's fluid or the chromic acid and spirit solution is advisable.

Picric acid—a saturated watery solution—stains the tissue of a yellow color. It removes the lime salts, and is used as a decalcifying agent.

Osmic acid, $\frac{1}{4}\%$ solution. Hardens quickly, within 24 hours, and stains fatty matters and the myelin of nerve fibres black. It is very useful for embryonic tissues, retina, nerve fibres, &c. After hardening wash in water, and keep in alcohol.

SOFTENING SOLUTIONS. To soften bone and teeth use *picric acid*, saturated solution; specially good for foetal bone; or *chromic* and *nitric acid* fluid, $\frac{1}{2}\%$ chromic acid solution, and to each 200 c.c. add 2 c.c. of nitric acid. It decalcifies bone in about two weeks, if solution is changed once or twice. After softening, wash thoroughly to get rid of the acid, and then transfer to spirit.

DISSOCIATING FLUIDS. These are useful for separating the elements of the tissue or softening the cement substance, so that the fibres can be more readily teased. The most suitable are:—

Iodized serum, very dilute *chromic acid*, and *bichromate of potash* solutions, 1 to 5,000; *dilute alcohol*, 1 to 2 parts of water. Very small bits should be placed in the fluid, and usually twenty-four or thirty-six hours is sufficient for the process.

CUTTING SECTIONS. Tissues hardened in the above-mentioned ways are ready for section which is most conveniently done "by hand" with an ordinary *razor*; one of those "made for the army," with a thin broad blade, is the best. If the bit is large enough it may be held in the hand; if small it must be enclosed in some easily cut material of about the same consistence as itself. For this purpose a convenient way is to make a slit in a piece of carrot or elder pith, or, better still, a bit of hardened liver, and enclose the tissue to be cut. Usually some form of *imbedding mixture* is employed, either white wax and olive oil, equal parts; or paraffine four parts, lard, one part. Cacao butter or gum may be used in the case of some delicate tissues, and in embryological work.

In imbedding proceed as follows:—Make a small oblong box of paper, $1\frac{1}{2} \times \frac{3}{4}$ inches, and fill it with the melted mixture, which must not be too hot. Take the bit of tissue from

the spirit, dry it thoroughly with blotting paper, and fix it in the wax and oil, near one end of the box, by means of a needle; then pour in enough of the mixture to cover the specimen; set aside for a few minutes until the fluid becomes firm, when the paper may be removed.

In cutting sections attend to the following directions:— Hold the wax mass in the left hand, between the forefinger and thumb, the razor in the right hand, grasped with the fingers and thumb, not held tightly in the palm. Cut rapidly from left to right, drawing the razor from heel to tip. The sections can be floated off the razor into spirit, with which, also, the blade must be kept constantly wetted. Keep the surface of the wax mass as level as possible. The razor must be very sharp, and requires frequent stropping. To become a successful section-cutter requires practice and some little dexterity. It is a good plan for the student to practice for some time on a large bit of hardened liver.

For cutting a large number of sections *microtomes* are employed, the chief of which are those of Rutherford, Williams, Schiefferdecker, and Ranvier. They are usually adapted for freezing with a mixture of snow and ice; some are arranged for freezing with an ether spray.

STAINING. In order to demonstrate details of structure it is essential that the sections should be steeped in some coloring fluid. Of these, the two most serviceable are carmine and logwood.

Carmine. Beale's fluid is very useful for fresh specimens, and is thus prepared: Dissolve carmine, grm. 1, in liq. ammon. fort., 3 c.c., gently warm, and add aqua. distillat., 120 c.c., and then filter. Add best glycerine, 30 c.c., and rectified spirit, 120 c.c. Keep in well-stoppered bottle.

Bits of tissue placed in this fluid stain in from twelve to twenty-four hours.

Klein's formula is as follows:—

Carmine, grms. 2; rub up with aqua. distillat., and then add liq. ammon. fort., c.c. 4., and aqua. distillat., c.c. 48. Mix and filter. Keep in a stoppered bottle. For staining, one drop of this in nine or ten of water. Sections from alcohol tint in about sixteen hours.

For rapid staining the sections may be placed in the undiluted fluid, in which they tint in a few minutes.

Logwood. I prefer the fluid made after Klein's formula. It is very constant, and the tint is a good violet. The solution is made as follows: Extract. Hæmatox, grms. 6; alumen, grms. 18. Mix thoroughly in a mortar. *Add gradually, whilst stirring:* Aqua distillat., c.c. 28. Filter, and to the filtrate add spirit. rect. ʒi.

For staining, add five or six drops to half a watch-glass of water; about dilute enough to enable print to be read through the solution. The dilute fluid must always be filtered. Sections from alcohol stain in from ten to fifteen minutes.

Other useful dyes are *Picro-carmin*, which has the advantage of giving a double tint to the tissues, some parts of which are stained yellow by the picric acid, others red, by the carmine. Thus the stroma of the frog's blood-corpuscles is stained yellow, and the nucleus red.

Among the aniline dyes* are several of great value, as *Mythyl-aniline*, used as a strong watery solution. It gives a double stain, a red violet and a blue violet. It is most serviceable in the examination of tissues which have undergone the pathological change known as amyloid degeneration. Any elements affected in this way are tinted red violet, the healthy parts blue violet. Sections can be mounted in Farrant's solution or glycerine—not in balsam, as the oil of cloves destroys the color.

Aniline blue-black. 1% solution in water; very useful for nerve tissues.

Aniline blue, Iodine green and *Rosein* are other dyes occasionally used.

Magenta (rosaniline nitrate) is useful for tinting fresh tissues, and in the irrigation of specimens when under observation.

Silver nitrate— $\frac{1}{2}$ – $\frac{1}{4}$ % solution. It stains the cement substance between the cells and the intercellular substance of connective tissue and cartilage, the black oxide being deposited under the action of light. Tissues must be fresh, and should be

* R. & J. Beck, of Philadelphia, keep a good supply of all staining fluids.

first washed in distilled water to remove the chlorides, and then placed in the solution for five or ten minutes until they have a greyish-white appearance. Remove, wash in water, and expose to bright light, when the tissue becomes brown, owing to a precipitation of the silver.

Gold chloride. $\frac{1}{2}$ -2 % solutions. Of great service in staining nerve fibrils and connective tissue cells. Tissues require to be steeped in it for half an hour to an hour, then expose to the light in water slightly acidulated with acetic acid. Stirling recommends the preliminary steeping of the tissue, as the cornea, in lemon juice for five minutes, then in the gold for half an hour; wash, and place in a mixture of formic acid, one part to four of water. In twenty-four hours the gold is completely reduced.

Osmic acid. $\frac{1}{2}$ - $\frac{1}{4}$ % solution. Hardens as well as stains. Useful for nerve fibres, the myelin of which it blackens, and for fatty tissues.

For details of double and treble staining the advanced student may consult the work of Mr. Henage Gibbes.

MOUNTING. Sections which have been hardened in alcohol and stained are, as a rule, mounted in dammar or Canada balsam. The method of procedure is as follows:—

(1.) Remove from the staining fluid to water, in order to wash away the superfluous dye. A minute or two is sufficient.

(2.) Transfer to alcohol—absolute is preferable. In this the section can remain for an indefinite period, but a few minutes will suffice to drive out the water.

(3.) Pick one or two of the thinnest sections, and place them on the centre of a glass slip; absorb the superfluous spirit with blotting paper, and add a drop of oil of cloves, which gradually clarifies the section by displacing the alcohol. A little practice soon enables one to tell when the specimen is sufficiently translucent.

(4.) Absorb the oil of cloves, and add a drop of balsam or dammar, and apply the top cover, being careful to exclude air-bubbles.

Dammar is made as follows: Mix equal parts of mastic, dammar, chloroform and turpentine, and filter.

The Canada Balsam is made by mixing equal parts of good Canada balsam and chloroform, and warm ; then filter.

Many preparations are mounted fresh from water or staining fluid in glycerine, glycerine jelly, or Farrant's solution, and they often show the minute details better than in balsam.

Farrant's solution consists of equal parts of glycerine and a watery solution (saturated) of arsenious acid. To this add gum-arabic, and allow the mixture to stand for several weeks, when it is filtered, and is then ready for use. It has the advantage over glycerine that it becomes hard, and so fixes the top cover. Bits of fresh tissues stained in Beale's carmine and mounted in glycerine will keep for years, if properly sealed at the edges. I have slides prepared in this way twelve years ago, as good now as when mounted.

To cement the edges of glycerine slides use balsam or gold-size, which may be applied with a small camel-hair brush. Be careful to remove all the superfluous glycerine from the margin of the top cover, otherwise the gold-size will not stick, and the preparation will eventually leak.

Carefully label each specimen, and keep the slides flat—not on their edges.

The student will need the following :—

Pair of small, fine-pointed scissors ; fine-pointed forceps ; two needles in handles ; a razor ; a section-lifter, made by flattening out the end of a bit of copper wire ; glass slips and top-covers ; watch glasses (½ dozen) ; labels, and a small box with trays, capable of holding 100 slides.

NORMAL HISTOLOGY.

AIR BUBBLES, GRANULES, &c.

AIR BUBBLES. Examine drop of saliva. Most of them are circular ; border is dark, centre clear. Press top cover down and get a variety of irregular forms. Study carefully, as they are of common occurrence in slides.

OIL DROPS. *Milk*; circular globules of variable size ; contrast with air bubbles. *Yolk of egg*; still smaller droplets of fat, with large yolk spheres among them. *Chyle*, from Thoracic duct ; fine molecular fat.

GRANULES. Rub up *gamboge* or *Indian ink* with water. Fine granule has no light centre ; coarse granule has light centre and dark border. Granules in fluid exhibit Brownian or molecular motion, due to thermal currents.

FIBRES. *Cotton*, flat, twisted ; *linen*, straight, often fissured ; *wool*, cylindrical, with characteristic imbrications ; *woody* ; examine slice of lead pencil, bits of boiled cabbage, turnip and carrot.

DUST. Examine slides of dust collected from different localities. Note the great diversity of irregular particles, bits of hairs and fibres of various sorts.

STARCH.—*Potato* ; scrape cut surface. Observe concentric lamination ; hilus, so-called nucleus, is eccentric. Add dilute iodine. Granules are large, shaped like an oyster shell. *Wheat* ; grains smaller, striæ faint, shape round or lenticular. Examine also rice, arrowroot, sago and oatmeal.

PROTOPLASM; CELLS.

TYPICAL ANIMAL CELL. Tiny mass of gelatinous substance, protoplasm, which is contractile and in which a nucleus can commonly be seen. There may or may not be an investing membrane, cell wall.

Study it in (1) the *Amœba* or *Proteus animalcule*, from meat or hay infusion, or stagnant water. Observe outer hyaline border, *ectosarc*, inner granular part, *endosarc*; nucleus; contractile vesicle, a clear space which appears and disappears; foreign bodies, diatoms, &c., inside it; change of form by processes or pseudopodia; change of place, locomotion. Sketch at intervals of 30 seconds.

(2) *White blood corpuscle* (blood amœba), *vide infra*.

These two bodies form the most suitable objects for studying the simple undifferentiated animal cell. The ultimate structure of protoplasm is reticular (intra-cellular network of Klein and Heitzmann). To see, examine superficial cuticular layer of frog or newt, after hardening in alcohol and staining in logwood.

Cells of the adult body are arranged in the form of tissues, as epithelium, gland tissues, etc. They do not often present a definite cell wall, with double contour, but the outer layer of protoplasm is more condensed and hardened. A delicate investing membrane can be seen in some epithelial cells. In many structures the cells have become differentiated to such a degree as to be scarcely recognizable; for example, muscle and nerve fibres.

VEGETABLE CELL. Only the very young cells of the embryo resemble the typical animal cell. All others have a distinct cell wall. Examine edge cells of leaf of *Vallisneria*. Observe cell wall, double contour; clear or slightly granular cell contents with a few green grains of chlorophyl; nucleus, eccentric. Examine the inner large

rectangular cells for the rotation of the protoplasm—*cyclosis*. The chlorophyl grains are carried in the protoplasmic currents. Examine cells of thin cuticle of sheath of onion. Observe the currents of protoplasm radiating from nucleus.

CELL MULTIPLICATION. *Fission.* May be seen occasionally in white blood corpuscle. In slipper animalcule (*Paramecium aurelia*) can be well followed. Get from gelatinous scum which forms in meat infusion after 4 or 5 days. Consult Klein's Atlas for neuclear changes in proliferating cells.

Gemmation, budding. Yeast plant; *vide infra*.

Endogenous mode; fission within cell membrane; look for in many unicellular plants, and in ova of snails and many entozoa.

Vacuolation. Examine preparation of mesoblast of embryo chick, or bit of rapidly growing sarcoma or cancer; clear spaces form in the protoplasm of the cell, and within this new cells originate either as buds from the wall or perhaps from the nucleus.

FUNGI.

Their study important ; (*a*) in relation to certain skin diseases ; (*b*) as agents in fermentation ; (*c*) as the supposed germs in many diseases.

Lower forms divided by Nägeli into three groups :—

(1) *Moulds*. Examine common mould, *Penicillium glaucum*. Observe *mycelium*, dense felt-work of interlacing fibres ; *hyphae*, the individual filaments of the mycelium, each hypha consisting of elongated cells with partitions between them ; vacuoles in the protoplasm ; ærial hyphæ bearing spores or *conidia*.

The *Achorion Schönleini* of Favus, *Trichophyton tonsurus* of Ringworm, *Microsporon furfur* of Pityriasis vesicolor and *Oidium albicans* of Thrush belong to this group.

(2) *Sprouting Fungi*, *Saccharomycetes*. Examine drop of yeast. Observe unicellular bodies, the Torula or *S. cerevisiæ*. Some are single, others arranged in chains. Each consists of granular protoplasm (with vacuoles) surrounded by a cell wall. Irrigate with magenta, protoplasm only stains. Note the buds or gemmæ ; they increase by gemmation.

These little bodies are the active agents in alcoholic fermentation ; they require O, and to get it have the power of breaking up such compounds as sugar, and in the process the constituent atoms of sugar re-arrange themselves into molecules of ethyl alcohol and carbonic dioxide.

(3) *Cleft-Fungi*, *Schizomycetes*,—*Bacteria*. Examine hay or meat infusion. Most of the forms can be seen in "fur" on the tongue. The following varieties are distinguished :—

(*a*) *Micrococci* or spherical bacteria. Examine epithelium of tongue. Observe among the scales, some which are very darkly granular, being infiltrated with minute spherical, motionless bodies, which resist the action of æther and acetic acid. They often occur in colonies or groups, and are common in all decomposing organic matters.

(b) *Elongated Bacteria*. *Bacterium termo*. Examine any decomposing infusion. Minute rod-shaped bodies, often in couples; length about twice or thrice the breadth; they move with an irregular progressive motion.

Examine the scum in top of decomposing infusion. Observe Bacteria, spherical and elongated, imbedded in a gelatinous matrix.

(c) *Bacillus*. Examine hay infusion; straight filaments, longer than *Bacterium*, jointed; motile: *B. anthracis* of Splenic fever resembles closely and perhaps is only a variety of *B. subtilis* of the hay infusion. Bacilli filaments—often called *leptothrix*—occur in “fur” of tongue.

(d) *Vibrio*; resembles the bacillus, but it is bent at the joints. Motion is undulating.

(e) *Spirillum*; spiral filaments, unjointed; motion screw-like, often rapid.

The members of the two last groups constitute what are known as the morphological or organized ferments, in contradistinction to the chemical or unorganized, as pepsin.

BLOOD.

HUMAN. To get drop, compress firmly the base of last phalanx of ring finger with the thumb and other fingers, and prick the congested pad with a sharp needle. Try to proportion the size of the drop so as to form a thin uniform layer beneath the top cover; if too thick a layer, absorb with blotting paper. Watch the corpuscles running together to form rolls or rouleaux—process of *nummulation*. If layer is too thin this cannot take place, and if too thick it is not well seen. In blood during high fever and in some violent diseases the corpuscles do not form rouleaux, but aggregate into irregular clumps.

Observe the following elements :—

Red Corpuscles. Circular biconcave disks. Watch an individual corpuscle and cause it to roll over by touching the top cover; in profile it is a short, blunt rod; the depressed centres and thick edges can be well seen. Owing to its biconcavity it presents a dark centre and light border, and *vice versa*, as the focus is changed. Do not mistake this appearance for a nucleus; color a light reddish yellow. Corpuscle is a semi-solid, viscous mass, without cell membrane or nucleus, and consists of a uniform stroma infiltrated with a coloring matter, hæmoglobin. Measure; average diameter $\frac{3}{1000}$ to $\frac{3}{800}$ of an inch, or 7.5 to 8 micromillimeters. Smaller forms are not uncommon in some healthy individuals, while in certain diseases very small red corpuscles (microcytes) are met with, $\frac{7}{1000}$ to $\frac{3}{1000}$ of an inch. On the other hand, larger forms may occur, $\frac{1}{1000}$ to $\frac{3}{2000}$ of an inch (giant forms).

Action of reagents. Add *water*; coloring matter diffuses, and leaves the pale stroma. Corpuscle seen then with difficulty. Study carefully, as these decolorized forms are frequently seen in urine and ejecta.

Add *salt solution* (1 or 2 per cent.); rouleaux do not form. Corpuscles become irregular, with jagged edges, *crenated*. Same

is seen if slide is exposed for a few minutes before the top cover is put on.

Add 1 per cent solution of *Tanin* ; coloring matter separates from the stroma and collects at the margin in one or two small dots.

White corpuscles. Proportion to colored about 1 to 400 or 500. Look for them in the clear spaces of the rouleaux ; small masses of granular protoplasm, circular when first seen ; a little larger than red corpuscle, but the size is very variable. Nucleus often indistinct. Amœboid movement begins a few minutes after withdrawal. Corpuscle attaches itself to the glass, and become flattened ; outline gets irregular from the protrusion of processes. To appreciate the changes, sketch at intervals of a minute. A slow creeping movement takes place. Corpuscle may become very flat ; note then the finely granular nature of the protoplasm, the nucleus, and often small vacuoles or clear spaces. The movement takes place slowly at ordinary temperatures, and is much more lively on the warm stage. A corpuscle with very coarse, dark granules, only partially filling the protoplasm, may sometimes be seen.

Examine mucous corpuscle from mucus of nose or mouth, or from mucus-cloud of urine, and pus corpuscles from abscess. They resemble closely the white blood corpuscle, and when warmed display amœboid changes. The term *leucocyte* is applied to these cells indifferently.

Action of reagents. *Water* causes the corpuscle to become pale and swell up. *Acetic acid* makes the nuclei very distinct. *Magenta* stains them. *Atropia* 1 to 2 % causes them to throw out peculiar, hyaline processes (Osler, Quart. Journal, Micr. 1874). A similar appearance is sometimes seen in mucous and pus corpuscles in urine.

Feeding white corpuscles. This is best done with newts blood. Add salt solution, in which fine particles of carmine or Indian ink are suspended, to a drop of blood ; surround top cover with parafine, and, if human blood, place on warm stage. The corpuscles are seen to take up the dark granules into their interior. With newts blood milk globules may be substituted

for the Indian ink. A striking experiment, which sometimes succeeds with active corpuscles of frog or newt, is to mix the blood with a tiny drop of human blood, the red corpuscles of which may be "eaten" by the colorless cells. I have seen a colorless corpuscle of the newt with four red corpuscles in its interior.

Study in connection with this the following :—

(1) The phlegm first hawked up in the morning ; many of the mucus cells contain dark grains which they have ingested.

(2) Specimen of carbonized lung, or, better still, of lung in Anthracosis. Note how many of the carbon grains are *fixed* in cells, some of which may be stretched and deformed to accommodate a large bit.

(3) Specimen of tissue near a recent extravasation. Note how many of the connective tissue cells have taken up the blood corpuscles. Section of brown induration of lung illustrates the same thing.

Fibrin-fibrils. Within two or three minutes after withdrawal, the blood drop coagulates by the separation of the fibrin, the delicate fibres of which are seen to pass in the clear spaces between the rouleaux. Beginners often have difficulty in seeing them. Sometimes the fibres are coarse, and the net work very dense ; this is particularly well seen in blood of patients with pyæmia.

Schultze's Granule Masses. In the blood of most persons, irregular aggregations of colorless granules can be seen in variable numbers. The masses range in size from a colorless blood corpuscle to collections 15 or 20 times as large. They are usually regarded as representing *débris* of colorless corpuscles, but I have shown that they are aggregation of minute discoid bodies, the nature of which is as yet unknown. They abound in many cachectic states and in the blood of many animals, notably young rats. Consult Schultze, Arch. f. Micros. Anat. Bd. I. ; Riess, Reichert's Archiv, 1872. Osler, Proceedings of Royal Soc. 1874.)

An hour or so after eating the blood often presents numerous fine particles, probably chylous.

Nucleated red blood corpuscles. Examine blood of foetus or new-born child. Here and there among the ordinary forms, a colored corpuscle may be found with a granular nucleus. They are commonly larger than the non-nucleated corpuscles. In adults they are never found in the blood in health, but I have met with them in cases Leucocythemia and in Pernicious Anæmia. They abound in ordinary red marrow which forms the most suitable object for their examination. In this tissue they are regarded as transitional forms between the colorless marrow cells and colored elements. *Vide Marrow.*

OTHER MAMMALS. All have blood elements similar to those of man, red, circular disks, except in camel tribe, in which corpuscles are elliptical. There is, however, a great difference in size. Measurements in micro-millimetres are as follows: Dog, 7·30; Ape, 7·35; Rabbit, 6·90; Sheep, 5·00; Horse, 5·43; Ox, 5·95; Cat, 5·50. Measure five corpuscles each of blood of cat, dog and man.

BIRDS, REPTILES, AMPHIBIA AND FISHES. Red corpuscles are oval and nucleated, the nucleus central, and causes a bulging on either side of the cell. Examine a slide of each. Frogs blood is particularly suitable for study of amoeboid movements of colorless elements and the action of reagents. Still better are the enormous corpuscles of the *Menobranchus lateralis*—the large "lizard of the lakes," common in the rivers and lakes of this continent.

BLOOD COUNTING. Estimate number of red globules in a cubic millimetre with Gowers Hæmacytometer or Malassez's *Compte Globule*. Average number per cubic mill, 5,000,000.

COLOR ESTIMATION. Use apparatus of Gowers or of Quincke.

BLOOD CRYSTALS. *Hæmoglobin.* Add small drop of rats blood to a drop of water, put on a top cover and surround with parafine. Hæmoglobin diffuses from the corpuscle and crystallizes, at first in small needles, which in time become large and form beautiful stellate masses.

Blood of guinea-pig may be treated in same way. The crystals do not keep well, but if mounted dry or in balsam may retain shape for some time.

Healthy human blood does not crystalize readily. From blood in Leucocythæmia beautiful crystals may be obtained.

Hæmin. Crystals of this derived coloring matter may be got in the following way : Dry a drop of blood on a slide, add a few grains of finely powdered salt, put on top cover and let a few drops of acetic acid run under ; warm gently over spirit lamp until bubbles are developed. When examined, a number of short prismatic crystals of a deep red color may be seen. Sometimes the acid must be added again or even a third time, and the slide again warmed before the crystals appear. This forms an important test for blood stains, as the presence of the crystals is positive evidence of the presence of blood, though, of course, it affords no information as to the creature from which it was derived.

Hæmatoidin, examine *corpus luteum*, or any old extravasation.

EPITHELIUM.

SQUAMOUS. Examine (1) scraping of surface of tongue; Observe large flattened cells isolated or in groups of 4 to 8; edges often folded. Nucleus small, centric.

(2) Vaginal mucus—cells have same appearance, often more folded.

(3) Cuticle of Frog—stain in carmine, mount in glycerine. Observe cells in contact, forming a continuous membrane, nuclei stained.

(4) Examine section of skin or cornea to see stratification of epithelium and gradual flattening of the cells as the surface is approached.

The squamous lining of serous membranes, blood and lymph vessels and lymph spaces is known as endothelium.

Demonstrate as follows by the *silver method*. Kill the animal, rabbit or frog, by bleeding; pencil the omentum or mesentery with $\frac{1}{4}$ % solution of silver nitrate, or, better, immerse in the solution for 5 or 10 minutes. Wash in water, expose to light until membrane becomes brown. Cut into small pieces, float from the water on to slide, absorb the water, and cover with and mount in glycerine. When examined, the silver is found to have stained black the uniting material between the cells, which are in this way beautifully mapped out. The nuclei are not stained. Note that the cells form only a single layer, and are not stratified as in epithelium. To demonstrate endothelium of lymphatics, kill rabbit by bleeding; brush central tendon of diaphragm with salt solution, and then pour over it $\frac{1}{4}$ % silver solution, and allow it to remain for 8 or 10 minutes; excise tendon and expose to light in distilled water. Cut pieces and mount, silvered side up, in glycerine.

GLANDULAR. Tease bit of deeper part of mucosa of stomach in salt solution. Cells are *spheroidal*. Examine teased bits or scrapings of liver and kidney. Cells are irregular in shape, protoplasm granular, nuclei distinct.

COLUMNAR. Tease very finely bit of mucosa of intestine of recently killed animal. Cells are cylindrical, tapering; ends pointed or bifid; base presents a seam or hem, which with very high power is seen to be striated. Protoplasm finely granular, nucleus oval, well defined. Cells are often seen in groups, and when looked at with bases uppermost they present a beautiful mosaic. These cells are very delicate, and the mucosa may require to be soaked in bichromate of potash for 24 hours. Good specimens may be obtained from intestine of child. Cells with swollen bases, or with basal hem removed, can be seen; they are called chalice or goblet cells, and result from the transformation of the protoplasm into mucin, which swells and may rupture the base of the cell.

TRANSITIONAL. Scraping of human bladder or pelvis of kidney. Observe flattened cells, with curved markings, granular protoplasm and large nuclei; others club-shaped with long tail-like processes, others again oval in shape. Study carefully, as all varieties are frequently met with in the urine.

CILIATED. Obtain from mouth of frog, gill or beard of oyster, or trachea of recently killed animal. Examine in salt solution. May be either spheroidal or columnar. The cilia are in constant motion, and cannot well be seen until the movement slackens or stops, when they appear as delicate hair-like outgrowths from the free border of the cell.

CONNECTIVE TISSUES.

Areolar, fibrous and elastic tissues, cartilage, bone and dentine are grouped together in this category. They all develop from the mesoblast, and frequently pass by substitution into one another.

AREOLAR TISSUE. Snip off a small bit of the subcutaneous tissue of a young animal and spread out carefully on glass slip, to which it will adhere and remain extended; add salt solution and cover. Observe the delicate fibres passing in all directions, some single, others in wavy bundles. Numerous interspaces, or areolæ, filled with lymph, exist between the fibres, and in this the connective tissue corpuscles can be seen; which are of two kinds, (1) the amœboid and (2) the fixed. Former are round, and resemble the colorless blood corpuscles, and are probably derived from the blood. The fixed are of very various shapes—spindles with long fibrils attached, or flat plate-like cells, with longitudinal divisions. Add acetic acid; the areolar fibres swell up and become indistinct, the corpuscles become more distinct.

The following tissues may be studied in connection with this: *Mucoid* or *gelatinous* tissue, which is found in the umbilical cord (Wharton's Jelly), in foetal skin and in vitreous humour. The tissue yields mucin on boiling. Tease bit of navel string in salt solution; observe the branching and anastomosing cells forming a sort of reticular net-work, in the meshes of which is the mucoid material.

Adenoid tissue, which forms the supporting framework of lymph glands and spleen and exists as diffuse areas in other parts. It consists of a dense net-work of fine fibrils, the meshes of which are closely filled with the lymph cells, which must be removed before the fibres can be seen. At the nodal points in the reticulum, nuclei are seen, but these probably belong to endothelial cells applied to the fibres. *Vide* lymph glands.

Neuroglia. The delicate net-work of fibres which supports the elements of the central nervous system. It appears to partake rather of the nature of elastic tissue. Examine transverse section of white substance of sp. cord.

WHITE FIBROUS TISSUE. Exists in tendons, ligaments and fibrous membranes. Consists of fasciculi or bundles of fibres, the ultimate elements of which are parallel fibrils, identical with those of areolar tissue.

Tease finely a small bit of any tendon, then add salt solution and cover. Note the wavy, parallel course of the fibres. The fibrils are indistinct, as they are united by a cement substance. Dilute acetic acid, 1 per cent., brings out oval nuclei. The intrafascicular spaces—which are lymph channels—with the tendon corpuscles can be well seen by cutting a transverse section of dried tendo Achillis; stain in Beale's carmine fluid, and mount in glycerine.

ELASTIC TISSUE. Tease bit of ligamentum nuchæ of sheep in salt solution. Fibres are coarse, branch and anastomose; ends curled. Add acetic acid; no change. Scrape off mucosa of trachea, and then strip off thin submucous tissue. Observe fine net-work of elastic fibres. Examine elastic layer of intima of artery—fenestrated coat of Henle. For continuous elastic membrane, study anterior lamina of cornea. In ordinary areolar tissue, after the addition of acetic acid, elastic fibrils may frequently be seen.

ADIPOSE TISSUE. Study silver preparation of mesentery. Numerous fat cells enclosed in a sort of mesh work of areolar tissue. Each cell consists of a membraneous vesicle filled with oil; often radiating crystals of margarin can be seen. Stain a bit of omentum in Beale's fluid, and mount in glycerine; the nuclei of the fat cells appear at one pole. Study in sub-cutaneous tissue of young rats the gradual conversion of the connective tissue corpuscles into fat cells, by the development of oil drops in the protoplasm.

PIGMENT TISSUE. Examine section of retina, the outermost layer of which consisted of flattened polygonal pigment cells. In rete mucosum of skin, cells are spheroidal. Tease bit of choroid of pig for stellate pigment cells. Examine tail of tadpole or web of frog's foot.

CARTILAGE. Protoplasmic cells imbedded in a matrix of variable character.

Varieties are : Cellular, Hyaline, Fibrous and Elastic.

Cellular. Examine (1) drum of ear of small frog. Cells closely packed, with little or no intervening matrix. (2) Section of chorda dorsalis of embryo.

Hyaline. Exists in laryngeal, tracheal, costal, articular and embryonal cartilages. Cut thin sections with a razor and examine fresh, in serum. Cells fill the spaces in the matrix, often 2 or 3 in one lacuna. When fresh the nuclei are large and distinct; the protoplasm is in close contact with the matrix, but it soon shrinks away unless immersed in some fluid, as auric chloride, which *fixes* them in position. In costal cartilages, oil drops are common in the cells. In epiphysal cartilage of tibia of young animal, the cells are fusiform, or elongated. In ossifying cartilage they are grouped in parallel rows. The matrix is homogeneous, or finely granular, with a dim ground-glass appearance. Picric acid preparation of human costal cartilage shows zonular arrangement of matrix round the cells. It is probable that the matrix is interpenetrated with a net-work of lymphatic lacunæ and canals.

Fibro-cartilage. Section of intervertebral disk or interarticular meniscus, hardened in alcohol, and stained with picrocarmine. Nucleated protoplasts scattered in a matrix of fibrous tissue, which may present a concentric arrangement round the cells. Examine a fresh bit teased in serum; add acetic acid, the fibres swell and become indistinct.

Elastic cartilage. Examine section of lobe of ear or epiglottis, hardened in alcohol or picric acid, and stained with picrocarmine. Cells are large, often fall out of the spaces in the preparation; the matrix consists of interlacing elastic fibres.

In epiglottis, part of the matrix is hyaline, and this variety may be regarded as hyaline cartilage permeated by elastic fibres. Examine fresh section in serum; add acetic acid, the fibrils are unaffected.

BONE. Examine good transverse sections of fibula of child or of small animal. With low power, observe medullary canal, surrounded by compact bone tissue, which presents a number of small, dark, circular spots—the Haversian canals—and little dark, oat-shaped bodies, the lacunæ, arranged concentrically around them. Note how the Haversian canals open on the periosteal and medullary surfaces by transverse branches. A lamellar arrangement can be seen at inner and outer margin (circumferential lamellæ). With high power observe, (1) the Haversian canal, which in fresh state contains a blood and lymph vessel; (2) around it in concentric rings are the lamellæ (primary), often not distinctly seen; (3) oval spaces in the lamellæ, the lacunæ, which have numerous fine prolongations, (4) the canaliculi, passing in all directions, opening into the Haversian canals and joining contiguous canaliculi. Each canal, with its lamellæ, lacunæ and canaliculi, is termed an Haversian system, and is more or less isolated from adjacent ones by intervening areas of bone, which are also laminated (interstitial lamellæ). A longitudinal section shows the Haversian canals in their long axis; they have many anastomosing branches. In these specimens all the spaces appear dark by transmitted light, as they are filled with air and dirt which has got in during the grinding of the section. Other important details may be ascertained in sections of bone decalcified in chromic acid ($\frac{1}{2}$ %) and nitric acid (1 %) solution, which must be changed frequently. Saturated picric acid solution answers same purpose. Stain sections in logwood or picrocarmine. The corpuscles in the lacunæ and the concentric laminæ are well shown. Sharpey's *perforating fibres*, which pin or peg the lamellæ together, can be found by stripping off thin laminæ from the decalcified bone. The perforating fibres may be seen projecting from some of the laminæ like nails through a board. A good preparation showing the bone corpuscles in the lacunæ may be made from the thin parietal bone

of a small animal (mouse) stained in Beale's carmine fluid and mounted in glycerine.

Study sections of developing bone, (*a*) in cartilage, from tibia of child; (*b*) in membrane—from parietal bone of embryo.

Marrow. Two kinds; *red*, in most spongy bones of adult and in all bones of infant; *yellow*, in long bones of adult. Examine a *small* drop squeezed from a rib with bone forceps; put on the top cover without any reagent, and get a uniformly thin layer. Observe (1) colorless elements—marrow cells—of various sizes, with large clear nuclei. Most of them are larger than colorless blood corpuscles, others smaller—lymphoid. Some of these elements are colorless blood cells. (2) Red corpuscles, usually very numerous. (3) Nucleated red corpuscles—larger than ordinary red cells, with distinct granular nuclei, sometimes eccentric. They are believed to be intermediate or transitional forms (Neumann) between the colorless marrow cells and the ordinary red corpuscles. I have traced the steps in the process (Centralblatt f. d. med. Wissenschaften, 1878; Lancet, Aug. 5rd, 1878). (4) Myeloplaxes, or giant cells, large protoplasmic masses with many nuclei. (5) Peculiar groups of red corpuscles, enclosed in indistinct cells, the so-called cells containing red blood corpuscles. The blood corpuscles undergo atrophy and ultimately become converted into collections of yellowish pigment, which may be seen in most specimens. (6) In marrow which has begun to decompose, Charcot's crystals may be seen—spindle-shaped—probably composed of tyrosin. (7) A few fibre cells of the matrix.

Yellow marrow consists chiefly of fat cells, with a few lymphoid cells.

MUSCULAR TISSUE.

Two forms, the unstriped or smooth and the striated.

UNSTRIPED. Met with in walls of gastro-intestinal canal, arteries uterus, bronchi and skin.

Soak bit of intestine or uterus for a couple of days in dilute bichromate of potash solution, or in a 20 % solution of nitric acid for 24 hours, in order to loosen the adhesion of the fibres. Tease a small bit very finely. The fibres are either fusiform, broad at the middle and tapering at the ends, which may be bifid, or they are flat ribbon-like. A rod-shaped nucleus exists in each fibre. A faint longitudinal striation can be seen in some cells. The bladder of frog or intestine of *ascaris lumbricoides*, denuded of epithelium, stained in carmine and mounted in glycerine show the fibres and nuclei very distinctly. *Vide* arteries and intestines for arrangement of the fibres.

STRIATED. Tease bit of sartorius of frog in salt solution.

Observe cylindrical fibres with distinct transverse striation ; slight longitudinal striation may be visible. Irrigate with water, when in a short time a clear swelling may be seen at the edge of the fibre ; this is the *sarcolemma* or fibre sheath, distended by imbibition of the water. Or it may be better shown by teasing out fibres, keeping them parallel, and laying the needle gently across them so as to break the muscle substance, which then retracts, leaving the clear sarcolemma. Add dilute acetic acid, observe the elongated nuclei, just within the sheath. In another specimen, study the arrangement of the sarcous substance in a fibre the striæ of which are very distinct. The striation is due to the existence of broad, dim bands (*the contractile disks*), alternating with narrow, clear bands (*the interstitial disks*.) In each dim band or contractile disc there may be seen in some specimens fine vertical rods (muscle rods of Schäfer). In the narrow, bright band a fine dark line divides

it transversely into two parts. This is *Krause's membrane*, a transverse membranous septum passing from the sarcolemma. By means of these septa the fibre is divided into a number of *muscle compartments*, each of which consists of a dim, contractile disk, bounded on either side by a clear disk. What is known as the cleavage of the fibre may take place in either direction; if longitudinally, dividing the fibre into a number of fibrils, in each of which the alternate light and dim areas can be seen; if transversely, splitting the fibre into a number of disks. Soaking muscle in 1 % chromic acid solution favours the former, and hydrochloric acid, 1 to 50, for a week, the latter. In the muscle fibres of the lobster it may sometimes be seen without any preparation. If the cleavage takes place in both directions at once little square bodies result—the sarcous elements of Bowman. To study living muscle, examine fibres of leg of *Dytiscus marginalis* or *Hydrophilus*—(the common water beetles). Observe the waves of contraction passing along the fibres. The same may be seen in sartorius fibres of a recently killed frog.

Muscle of Heart. Tease finely bit of heart muscle from person recently dead. Observe (1) the short fibres, consisting of oblong or square muscle cells, which are joined end to end by narrow band of connecting substance; (2) the ovoid nucleus, centric, often very pale; (3) absence of sarcolemma; (4) some of the fibres branch.

The striæ are very fine, and there are often tiny fat droplets or brown pigment grains in the fibres.

NERVE TISSUE.

There are two varieties : (1) nerve fibres ; (2) nerve cells.

NERVE FIBRES. (a) Medullated or white. (b) Non-medullated or grey.

Medullated. Exist in cerebro-spinal nerves and in white substance of brain and spinal cord.

Tease carefully bit of sciatic nerve of frog in serum or salt solution ; a good preparation will show nearly all details.

Each fibre consists of (1) an external elastic membrane, the sheath of Schwann. In some fibres, hard to see, and represented only by the delicate outer line. Oval nuclei occur at intervals beneath it ; best seen by subsequent irrigation with picrocarmine. (2) The medulla or white substance of Schwann, composed of a highly refractile, viscid material, called myelin. It is situated just within the sheath of Schwann, and may be recognized by its double contour. The myelin soon changes, and may be seen exuding in drops from the cut ends. These alterations are best seen in white matter of brain or spinal cord, where the medulla has no sheath. The medulla presents interruptions in its course, the sheath of Schwann dipping in and forming a constriction—the node of Ranvier. The portion of the nerve between the nodes is called an interannular segment. The medulla is penetrated by a fine network of fibres (Kühne and Ewald). (3) The axis cylinder, a pale, narrow band in the centre of each fibre. It is sometimes seen projecting for a short distance from the divided end of the nerve. It is composed of delicate fibrillæ (Schultze), and a faint longitudinal striation may indicate their presence. The axis is the essential part of the fibre, and is continuous through the interannular segments.

Study specimens stained with osmic acid and with silver nitrate to show Ranvier's nodes.

Study transverse section of sciatic, hardened in chromic

acid and spirit solution, then in alcohol and stained in logwood or carmine. Observe the numerous nerve bundles surrounded by the *neurilemma* or *epineurium*; each bundle or fasciculus has a special connective tissue sheath—*perineurium*, while between the individual fibres of each bundle there is a delicate tissue, the *endoneurium*. The axis cylinder alone of each fibre is stained.

Non-medullated. Exist in sympathetic system, olfactory nerve, and here and there as isolated fibres in cerebro-spinal nerves. Examine fresh and osmic acid preparations. Fibres form pale, flat filaments, with only the axis cylinder and the sheath of Schwann. The nuclei are numerous, and the fibres are faintly striated.

Nerve Endings. (1) In fine plexus of fibres, representing probably the fibrillæ of axis cylinder. Study section of cornea treated with gold chloride; minute beaded fibrils between the epithelial cells. (2) In modified cells, as in retina, cochlea and olfactory membrane. (3) In peculiar terminal organs, as (a) Tactile corpuscles (Wagner, Meissner,) in papillæ of skin. (b) End bulbs (Krause) found in conjunctiva, lips, glans penis and clitoris; peculiar ovoid bodies enclosed in a connective tissue capsule. (c) Pacinian corpuscles. May be got in nerves of fingers, but most readily in mesentery of cat, where they can be easily seen as clear, oval bodies. Examine fresh, or in glycerine after staining with Beale's carmine. With low power observe general concentric lamination; the nerve penetrating the centre. With high power it can be seen that only axis cylinder enters; the medulla disappears. (4) In striated muscle, by granular nucleated bodies beneath the sarcolemma—*motorial end-plate*. Best seen in subcutaneous muscles of snakes. In unstriated muscle, nerve fibres have been traced between the cells, and according to some authors a penetration of the protoplasm takes place.

NERVE CELLS. In grey matter of brain and spinal cord, and in ganglia of sympathetic system.

Examine (1) ganglion of sympathetic of small animal, teased carefully in serum. (2) Bit of grey matter of anterior cornu of spinal cord of man or ox, soaked for 48 hours in

Müller's fluid or $\frac{1}{8}$ % bichromate of potash. The cells are somewhat difficult to isolate with the processes intact, and they are perhaps better studied in sections of hardened cord. Nerve cells vary much in size ; the largest are those of anterior cornua of spinal cord and in the cerebellum, the smallest are in grey matter of cerebrum. The protoplasm is granular, faintly striated, often impregnated with pigment grains, the nucleus large, vesicular, the nucleolus distinct. They possess a variable number of processes, and have been divided into uni—, bi—, and multipolar cells. It is not easy to trace the processes, but there can be little doubt that directly or indirectly they become continuous with nerve fibres, all of which may be said to originate in nerve cells.

SPINAL CORD. Harden bits of fresh cord of man or of cat in either Müller's fluid, bichromate of potash solution, 2 %, or bichromate of ammonia, 3 or 4 %. Finish the hardening process with spirit. Stain sections in logwood, carmine or aniline blue-black.

Examine section with low power first. Observe, (1) the anterior and posterior median fissures. (2) The pia mater, surrounding the cord and sending prolongations into the fissures, and at irregular intervals into the substance. (3) The central grey matter, with anterior and posterior cornua and commissure (grey), in middle of which is (4) the central canal. The grey matter is usually the most deeply stained. (5) The white matter, anterior, posterior and lateral columns, and anterior white commissure. (6) The nerve roots, which may perhaps be seen.

With high power, observe in *white substance*, (1) the cut ends of the nerve fibres, consisting of the axis cylinder deeply stained, surrounded by an unstained medulla ; they vary much in size ; compare the large ones of anterior with those of the posterior columns. (2) The connective tissue, enclosing the fibres in a sort of mesh-work. This is the neuroglia which is continuous with the septa dipping in from the pia mater. It appears to consist of a matrix traversed by fine fibres, among which small branched corpuscles may be seen. Some elements of the neuroglia resist peptic digestion, and are probably of an elastic or keratoid nature (Kühue and Ewald). In

grey matter, observe (1) the nerve cells, collected chiefly into certain groups, of which there are three well marked in anterior cornu, and one in posterior horn, just behind the grey commissure, known as Clarke's column. Those of anterior horns are large, and present numerous processes. One of these is unbranched, and may be traced for some distance; it is called the *axis cylinder process*, and is believed to represent the origin of one of the nerves of the anterior root. The other processes (called *protoplasmic* by Gerlach) branch and divide; their fine ramifications are believed to unite with those of other cells. Stricker, however, regards them as connective tissue processes and fibres. The cells of posterior horns are few in number and small. The space about some of the cells is regarded as a lymph space. (2) The nerve fibres, very minute, chiefly non-medullated, passing in all directions; they are best seen in the *grey commissure*. (3) The neuroglia, which appears like a granular matrix, but is probably reticular. It is abundant at one part of posterior cornua—the *substantia gelatinosa*. The *central canal* varies in size and shape. It is lined with cylindrical ciliated cells.

CEREBRUM. Same modes of preparation as cord. Great care must be taken to get vertical sections, or rather to get them exactly, in the plane of the fibres.

The cerebrum is made up of (1) the grey cortical layer; (2) the white medullary substance; (3) the basal ganglia.

A section of *cortical grey matter* usually shows five layers: The *first layer*, external, $\frac{1}{10}$ the thickness of whole cortex, is composed chiefly of neuroglia fibres, with very few cells. The *second layer* consists of small, closely packed pyramidal cells with processes. The *third layer*, wider than the second, contains nerve elements of the same kind, but they are larger (some very large, the so-called giant cells of the cortex), and not so closely packed; hence this layer looks lighter. The apices of the cells point to the cortex, and from the base processes are given off, one of which forms an axis cylinder. The *fourth layer*, narrower than the third, consists of small, closely packed, angular cells. In some convolutions larger cells occur. The *fifth layer*, broader than the fourth, gradually shades into the

white substance. It contains irregularly fusiform cells. This five-laminated arrangement of the cortex is best seen in the convolutions of the motor area. According to Bevan Lewis, over the greater part of the hemispheres there are six layers; the additional stratum, placed between the third and fourth layers, consists of small pyramidal and angular cells. In the third layer some of the nerve fibres may be seen to take a downward course towards the white matter, and in the fourth and fifth strata they form delicate bundles passing between groups of the cells. The neuroglia appears as a homogeneous or granular matrix, but in good preparations it can be seen to be fibrillar, and contains small branched cells.

The *white matter* is composed of medullated fibres of various sizes; most of them much smaller than spinal or peripheral nerve fibres. They often present varicose or bead-like swellings.

The *basal ganglia* are made up of grey and white nerve matter of essentially the same structure, but differing in arrangement.

CEREBELLUM. Vertical section, prepared in same way as cerebrum. With low power, notice the foliated or dendritic appearance. Three layers are to be seen in the *grey matter*; (1) an external, composed of a neuroglia framework, a few nerve cells, and numerous branched processes of, (2) the cells of Purkinje, which form the second layer. These are large ganglion cells, the extensions of which are chiefly into the outer layer, but an axis cylinder process is stated to pass down into the next; (3) the granular layer, made up of closely packed small corpuscles. The white matter is like that of the cerebrum.

BLOOD VESSELS.

ARTERIES. General structure of a medium-sized vessel is as follows :

There are three coats. (1) *Tunica intima*, consisting of (a) an endothelial lining, composed of flattened cell plates ; (b) sub-endothelial connective tissue with corpuscles, branched and unbranched ; (c) an elastic lamina, often perforated, the fenestrated membrane of Henle. (2) *Tunica media*, made up of circularly arranged muscle cells, with a variable amount of white fibrous and elastic tissues. (3) *Tunica adventitia*, composed of fibrous and elastic elements, and in large vessels muscle fibres. In large arteries the elastic, in small arteries the muscular, tissue predominates.

Examine (1) small artery of pia mater of human or sheep's brain in salt solution. The straight arteries passing in at the perforated spaces are the most suitable, as with care a long vessel may be obtained, and the transition from medium-sized artery to small arteriole can be traced. Add acetic acid to develop the nuclei of muscle fibres and to determine the elastic elements. Stain a bit in carmine and mount in glycerine. (2) Sections of the aorta and the radial artery, hardened in bichromate of potash or chromic acid and spirit ; stained in logwood. In aorta, notice in the *media* the alternate arrangement of elastic laminae and muscle fibres. (3) A silvered preparation showing the elongated endothelial cells.

VEINS. Essentially the same structure as arteries ; the chief points of difference are in the thinness of the coats, and the slight development of the muscle fibres in the *media* and of the internal elastic layer, which is seldom fenestrated. The *adventitia* is sometimes provided with muscle elements.

CAPILLARIES. Minute tubules, composed of endothelial cells, interposed between the arteries and veins. The cells are elongated, with dentated margins, and require for their demonstration the action of silver nitrate.

Examine (1) bit of grey matter of cerebrum, teased gently

in salt solution. The capillaries are seen as structureless tubules, with oval nuclei. (2) A silver preparation for the endothelia.

In certain parts are ensheathed arteries and capillaries in a membrane—lymphatic—which can be shown to be lined by endothelium. This is what is known as the perivascular lymph space. It can be seen in mesenteric vessels of frog, in those of the nictitating membrane of same animal, and in the vessels of the pia mater.

CIRCULATION OF BLOOD. Study in web of foot, tongue, mesentery or lung of frog or tail of tadpole. The first and last objects are the most suitable for the student. Inject into the dorsal lymph sac of a small frog 4 or 5 drops of curare solution ($\frac{1}{4}$ %). When the animal is paralysed place it on a bit of card-board, 6×2 inches, with a V-shaped notch cut out of the middle of one end. Fix the web over this by threads tied round the toes, and made fast in little slits in the card-board. Wet the web, and put on a small, thin bit of top cover. If a tadpole is used, put it in a watch glass with a few drops of the curare solution for a few minutes until it ceases to wriggle. Place on slide with a little water, and put a thin cover glass on the tail.

With low power, observe the arteries breaking up into the capillaries. The stream in these is very rapid, and it may be noticed to be more so in the centre than near the wall (still layer). The veins have thinner walls and the blood current is slower. The stellate pigment cells are well seen. With high power, study the capillary stream. The corpuscles pass in single file and wriggle in and out through the devious paths, often bending and displaying the elastic nature of the stroma. The colourless corpuscles pass along less briskly, and in the veins may frequently be seen hugging the vessel wall, as if reluctant to move on. For studying the *migration* of the white blood corpuscles the tail of the tadpole is most suitable, and the process may be watched without difficulty. Patience, however, is required, as it may take a couple of hours for a corpuscle to pass through. The mesentery and tongue of frog may also be used for this purpose; stimulation with a tiny drop of ammonia quickly excites the process, and the red corpuscles also pass out (*diapadesis*) at the focus of inflammation so excited.

LYMPHATIC SYSTEM.

LYMPH VESSELS. Capillary lymphatics are best studied in a silvered preparation of central tendon. (*Vide p. 11.*) They consist of a single layer of squamous cells, united by a cement substance, which is stained by the silver. Observe the plexus of large and small vessels, some with bulgings in their course. In the larger ones a valve may be seen. The capillaries are believed to originate in the interspaces of the tissues (*serous canaliculi*).

The lacteal vessels can sometimes be well seen in villi removed from an animal killed during digestion.

Examine transverse section of thoracic duct of horse; structure same as that of a vein.

LYMPH SACS. The subdural and subarachnoid spaces of brain and cord, the pleura, pericardium and peritoneum are in reality lymph sacs. The former, with their extensions around the cerebral and spinal nerves, constitute a closed system. (Key and Retzius.) The latter stand in open communication with the lymph vessels by means of orifices called *stomata*. These are best seen in the silvered septum of the large lymph sac in the abdomen of frog.

LYMPH GLANDS. They may be regarded as nodes or collections of adenoid tissue in the course of the lymph vessels. An afferent branch enters, and an afferent leaves, each gland. A firm capsule of fibrous tissue surrounds it and sends prolongations, *trabeculae*, into the substance, dividing it into alveoli, which consist of a delicate network, in the meshes of which are the lymph corpuscles. In the cortical part the adenoid tissue in the spaces between the septa forms ovoid or globular bodies—the *lymph follicles*; but in the deeper or medullary part is arranged as cord-like structures—the *follicular cords*. The lymph passes through the gland in certain spaces or sinuses, lined with endothelium, which exist between the trabeculae and the gland tissue.

Tease in salt solution a bit of fresh lymph gland. Observe the lymph corpuscles—*leucocytes*—isolated and collected into dense groups. They are a little smaller than white blood corpuscles, and the nucleus is proportionately larger. Other larger cells may sometimes be seen. At edges of well teased bits the fine adenoid reticulum may perhaps be seen, and here and there a nucleated fibre cell of the trabeculæ.

Harden gland in Müller's fluid (ten days) or picric acid (24 hours), and then in alcohol. Cut very thin sections, stain in log-wood or picrocarmine. The lymph corpuscles crowd the meshes so closely that the details are not well seen until some of them are removed, either by prolonged shaking of the section in a test tube with water, or by pencilling. The lymph sinuses can be shown by injecting a gland with Prussian-blue solution.

The Spleen, Thymus and Thyroid glands and the Supra-renal capsules may be considered with the lymphatic glands; they form the so-called ductless or blood-vascular glands.

SPLEEN. Tease a small bit of fresh spleen pulp of man in serum or salt solution; or, better still, take a very small portion and let the top-cover flatten it out as a thin layer. Observe (1) the red blood corpuscles, very numerous. (2) Colourless elements, some of which are white blood corpuscles; others, a little smaller, are the cells proper of the pulp. They vary a good deal in size; the nuclei are usually distinct; smaller forms, without nuclei, may be seen. (3) Cells containing red blood corpuscles. Very variable; in some specimens rare, in others abundant. All stages can be traced between cells holding perfect corpuscles and those enclosing yellowish brown pigment. The red corpuscles undergo disintegration in this way. (4) Nucleated red corpuscles, similar to those of the marrow, but not so abundant or so constant as in that tissue. (5) Elongated fibre cells of the trabeculæ.

From a gland in which they are distinct, pick out carefully a Malpighian corpuscle and tease in salt solution. Observe the lymph cells—*leucocytes*—of which it is composed.

For sections, harden bits of gland of cat in Müller's fluid or dilute chromic acid, $\frac{1}{6}$ to $\frac{1}{4}$ %, and then in alcohol. Observe (1) capsule made up of fibrous tissue, in some animals mingled

with elastic fibres and muscle elements. It sends prolongations into the substance—the trabeculæ—which constitute the framework, the meshes of which enclose the spleen pulp. (2) The Malpighian corpuscles, localized accumulations of lymph cells in the course of an artery. (3) The spleen pulp, which makes up the great mass of the section, and in logwood specimens appears composed of blue-stained cells, with red blood corpuscles. The arrangement of the elements of the pulp is hard to make out. There is a reticular net-work in the meshes of which the cells lie. No capillaries exist, but the smaller arterial branches open directly into the meshes of the pulp, and from the same the veinlets take their origin. The arrangement is similar to the lymph sinuses in the lymphatic glands.

The adenoid net-work is well seen in the enlarged and hard spleen of chronic valvular disease or of leucocythemia.

THYMUS. Examine section of gland of infant, hardened in Müller's fluid and alcohol. Observe the capsule, with its prolongations enclosing the follicles, which consist of a reticulated adenoid tissue with lymph corpuscles. In the central part the concentric corpuscles of Hassall may be seen, curious concentrically arranged epithelial cells, resembling the cell-nests in epithelioma.

THYROID. Harden in same way as Thymus.

A section shows numerous gland vesicles, surrounded by trabecular prolongations of the capsule. Each vesicle consists of a basement membrane, lining which is a layer of epithelial cells, somewhat columnar in form. The central space of the vesicle or alveolus is filled with a yellowish fluid, often mixed with the *débris* of cells and blood corpuscles. The vesicles are frequently filled with a semi-gelatinous colloïd substance, and it is the great increase of this which causes *goître*.

SUPRA-RENAL CAPSULES. Prepare in same way as Thymus. Two portions can be recognized, cortical and medullary. A firm capsule invests the gland and sends septa into the substance, which divide the cortical part into a number of elongated compartments, in which the gland tissue is included. Near the capsule these are small, like closed vesicles, but in the deeper

parts they form elongated cell-cylinders. The cells differ in appearance; in the outer part they are coarsely granular, with fat droplets in their interior; in the deeper parts they often contain brown pigment. The medulla consists of a matrix of connective tissue, with corpuscles of irregular forms in its meshes; some are rounded, others branched, and some present a remarkable resemblance to ganglion cells.

ALIMENTARY CANAL AND ITS GLANDS.

TOOTH. Prepare in same way as bone. In a longitudinal section observe : (1) Pulp-cavity ; (2) Dentine ; (3) Enamel ; (4) Crusta petrosa.

The *dentine* or *ivory* everywhere surrounds the pulp cavity, and is composed of an animal matrix, impregnated with lime salts. A series of tubes, the *dentinal canals*, pass through it from the pulp cavity, running at right angles, dividing dichotomously and anastomosing with each other. Delicate sheaths (Neuman's) line the canals which contains the dentine fibres, prolongations of the odontoblasts of the pulp. At the outer margin of the dentine irregular spaces are seen—interglobular spaces of Czermak.

The *enamel* surrounds the dentine above the gum line, and consists of a series of polyhedral columns set upon, and at right angles to, the dentine. Wavy markings or stripes cross the enamel prisms. In cross section they look like a tessellated pavement.

The *crusta petrosa* surrounds the dentine in the socket ; its structure is that of bone.

The *pulp*. Break across a tooth of a young animal. Examine fresh or after immersion in $\frac{1}{2}$ % solution of osmic acid for 24 hours. It is made up of a delicate connective tissue, with numerous blood vessels and nerve fibres ; the latter pass towards the dentine, but it is doubtful whether they enter its tubes. Towards the surface of the pulp there is a layer of cells—odontoblasts—which send off numerous processes into the dentine tubes, forming the dentinal fibres, and into the pulp, uniting with other cells.

TONGUE. Harden bit of organ of man or of cat in chromic acid and spirit solution for ten days.

Mucous membrane is covered with squamous cells—best seen in a scraping of the surface—and presents three varieties of

papillæ—the filiform, fungiform and circumvalate, together with numerous mucous glands. Smaller papillæ, similar to those of the skin, exist all over the membrane and in the larger papillæ. In the epithelial coating of the fungiform and circumvalate papillæ, ovoid, flask-shaped bodies occur, the so-called taste-goblets; these are curious structures, composed of modified epithelial cells, which are believed by many to be connected in some way with the nerves. At base of organ, about the circumvalate papillæ, are numerous elevated bodies, consisting of aggregations of lymphoid or adenoid tissue.

The muscle fibres of the tongue are striated, and often branch. The section through cat's tongue makes a beautiful preparation, from the numerous muscle bundles running in different directions. Good preparations, showing papillæ with nerves, and the branching of the muscle fibres can be obtained from the tongue of the frog—preferably the tree frog—stained in Beale's carmine and mounted in glycerine.

SALIVARY GLANDS. Two classes. (Heidenhain, Hermann's Handbuch, Bd. v.) (1) The true salivary glands, which furnish a thin, fluid secretion, usually amylolytic. To this belong the parotid of man and most mammals and the submaxillary gland of the rabbit. (2) Mucous glands, which secrete a tenaceous fluid, rich in mucin; to this class belong the submaxillary and sublingual. The submaxillary gland of man is of mixed character—muco-salivary. Tease fresh specimens in serum. Sections may be made after hardening in absolute alcohol or the chromic acid and spirit solution. They are compound acinous or racemose glands, lobulated, and intersected with connective tissue septa. The ducts ramify through the lobules, and the acini are grouped about their terminations. Each acinus consists of a basement membrane (tunica propria), composed of branched and flattened cells, within which are placed the true secreting cells. These vary in appearance in the different glands, and in states of rest and activity. In the true salivary, they are round or polygonal, with dark granules and angular nuclei. In the mucous glands two kinds of cells are distinguished; large, clear epithelial cells, nearly filling the lumen

of the acinus and with a small nucleus close to the basement membrane; and very granular cells, dispersed at intervals between the mucous cells and the membrana propria; they are of an irregular, half-moon shape, and are known as the semi-lunes of Gianuzzi. The gland ducts are at first small and have a flattened epithelium; in the larger branches the cells are columnar. The termination of nerves in the cells of the glands, as described by Pflüger, has not been confirmed.

TONSILS. Harden in chromic acid and spirit for two weeks.

Each tonsil consists of from 10 to 18 nodular masses of lymphoid tissue, very like a Peyer's gland. On the surface are small crypts or slit-like depressions, and it is about these that the little glands are arranged. The crypts are often filled with epithelial *débris*, particularly in slight inflammatory conditions, when the lymph follicles enlarge and discharge a greyish-yellow material. Squamous cells cover the surface of the gland.

ESOPHAGUS. Distend a portion of gullet with chromic acid and spirit solution. Suspend in the same. In this way the folds are obliterated. Finish the hardening in alcohol.

Sections show (1) mucosa, composed of stratified squamous cells. (2) In its deeper part the muscularis mucosæ, consisting of longitudinal unstriped cells. (3) Sub-mucosa, of areolar tissue, with numerous mucous glands, the ducts of which may be traced through the epithelium. (4) The muscular coat, consisting of unstriped fibres arranged in an outer longitudinal and an inner circular layer. In the upper part the muscularis is made up of striated fibres. The nerve supply is abundant, and in the striped fibres the motorial end-plates are very numerous. (Ranvier).

STOMACH. Harden bits from pyloric end and fundus, either at once in absolute alcohol or after a preliminary immersion in the chromic acid and spirit solution. Stain in logwood.

Section, examined with low power, shows (1) the mucosa, tubular glands set side by side. (2) The muscularis mucosæ, a thin layer of unstriped muscle fibres, placed at the bases of the tubules and sending up fibres between them. (3) The sub-mucosa, com-

posed of connective tissue, and containing the blood vessels and nerves. (4) The muscular coat, made up of two layers, longitudinal and circular, of unstriated fibres; in some places a third layer can be seen. (5) The serous or peritoneal coating. With high power examine mucosa, which presents (1) the *surface epithelium*, cylindrical in form, narrow basal border, protoplasm clear in outer, granular in inner, part. They are mucus-forming cells, and often present clear dilatations or appear open at the end—cup or chalice cells. This probably represents their active condition. These cells show well in the sections, but it is better to study them in fresh state, teased in serum. (2) The *peptic* glands, which exist over the entire mucosa except in the pyloric region. Each consists of a simple tubular gland, with basement membrane and cells. The columnar epithelium of the surface extends for about one-fourth of the length of the tube; this is called by some the duct, and it is separated from the lower part by a narrow portion, the neck. Two sorts of cells line the gland proper, one finely granular, cubical or polyhedral in form, and occupying a more central position—the *central cells* or *principal cells* of Heidenhain; the other larger, coarsely granular, irregularly placed, more external, and frequently forming irregular bulgings on the side of the gland; these are called the *parietal* or *peptic* cells. The central cells are the most numerous. The parietal cells are small in the fasting state, and increase in size during digestion. Heidenhain adduces evidence to show that the parietal cells secrete the acid, and the central cells the pepsine. (3) The *pyloric* or *mucous* glands are larger, longer, often branched at the end, and are lined throughout with columnar epithelium. In the deeper parts the cells are more cubical, and resemble somewhat the central cells of the peptic glands. They secrete mucus, and probably also pepsine, as this substance can be obtained from the pyloric mucosa.

Localized collections of adenoid tissue, lymphoid follicles, sometimes occur in the mucosa. I have seen them in children as distinct as the solitary glands of intestine.

SMALL INTESTINE. Prepare in same way as stomach. Study transverse section of ileum, first with low power. Observe arrange-

ment of coats similar to stomach, serous ; muscular, two layers, inner circular and outer longitudinal ; submucous and mucous. With high power study the mucosa, which presents the following parts for examination :—(1) The *surface epithelium*, columnar, with numerous goblet cells. The free border of each cell presents a distinct band or seam, which is striated. Whether these striæ represent pores, or rods, or extensions of the fibrils of the cell protoplasm (Klein), is not yet settled. When *in situ*, and looked at from above, the cells are seen to be polyhedral, and the ends, united by a cement substance, form a beautiful pavement mosaic. Keep a kitten without food for five or six hours, then give it milk, and two hours after examine teased bit of the upper layer of mucosa in serum. The epithelial cells are seen to be loaded with fat globules. These cells are the immediate agents in the absorption of fat. Watney states that the fatty particles pass through the cement substance. (2) *Lieberkühn's glands*, simple tubular structures, which occur throughout entire mucosa of both small and large bowel. Each consists of a structureless membrana propria, on the inner surface of which are columnar epithelial cells, some of which are of the goblet variety. At the bases and between the tubules there is a delicate adenoid tissue. (3) *Villi*, minute conical projections of the mucosa, composed of (a) cap or coating of cylindrical cells ; (b) a matrix of connective tissue ; (c) a rich plexus of capillaries just beneath the epithelium ; (d) a few unstriped muscle fibres, which pass up from the muscularis mucosæ ; (e) a central lacteal vessel, which probably originates in the lymph spaces of the connective tissue stroma. (4) *Peyer's glands*, consisting of solitary or lenticular follicles, and agminated or patches of Peyer, which only occur in the lower part of jejunum and ileum. A "patch" is merely an aggregation of the solitary glands. They are spheroidal, or pear-shaped, and exist in the mucosa and submucosa ; they often project on the surface, and are then only covered with the epithelium. Each is made up of a delicate fibrous sheath, enclosing lymph cells in an adenoid reticulum. They are in reality minute lymph glands.

Brunner's glands, seen in section of first part of duodenum, resemble somewhat the pyloric glands of the stomach, but are

larger, and lie in the sub-mucosa. They are compound tubular structures, and the diverticula—lined with columnar cells—discharge by a common duct.

The *muscularis mucosæ* resembles that of stomach.

In the *sub-mucosa*, besides the connective tissue and blood-vessels, there may be seen groups of ganglion cells, the nerve corpuscles of Meissner's plexus.

LARGE INTESTINE. Prepare as stomach. Its structure is similar to that of small bowel, except that it has no villi or patches of Peyer; the longitudinal muscle coat is collected into three bands, and the serous coat contains in places collections of adipose tissue (*appendices epiploicæ*). The solitary follicles are numerous; the crypts of Lieberkühn contain a larger number of goblet cells, and are probably only mucous glands.

Blood-vessels of stomach and intestines. Examine injected specimens. Observe the rich plexus of capillaries in the villi, and in an opaque preparation the dense net-work about the orifices of the peptic glands and of Lieberkühn's crypts.

Nerves. A double plexus can be demonstrated by means of gold chloride. Auerbach's exists between the circular and longitudinal muscle coats, and forms a beautiful wide-meshed plexus, in the nodal points of which are numerous ganglion cells. A similar network, *plexus myentericus* of Meissner, exists in the sub-mucosa.

PANCREAS. Harden in absolute alcohol, and stain in carmine.

It is a compound tubular gland, made up of lobules, united by connective tissue; each lobule is composed of a number of tubular alveoli, arranged around a terminal duct, the epithelium of which is flattened, while that of the larger collecting ducts is cylindrical. The alveoli are lined with columnar or blunt-pointed cells, placed on a basement membrane, and arranged round a very narrow lumen. The external part of the cell-protoplasm, next the *membrana propria*, is clear, and stains deeply; the internal portion is darkly granular. The appearance of the cells changes remarkably in different states of the gland, *i.e.*, when active during digestion, and when quiescent in fasting. In the latter state the granular zone occupies almost the entire

cell, and at this time the gland is rich in ferments. During digestion the granular part becomes much less, and the cell smaller. Heidenhain thinks that the granular matter represents the zymogen or mother ferment of the Trypsin, the proteolytic ferment of the secretion. Fine passages between the cells have been described (Langerhans), but their significance is doubtful.

LIVER. Harden bits of liver of pig and of man in Müller's fluid (two weeks), and then in alcohol.

The liver is made up of small lobules or acini of secreting cells, together with connective tissue, blood and bile vessels.

The *acini* are irregular polyhedral masses, about 4×1 mm., placed on small branches of the hepatic veins as sessile berries are on their stalks. They are best seen in the liver of the pig, as in that animal the lobules are invested by a distinct fibrous sheath, whereas in man the acini are not thus isolated. Observe with low power in the section how the liver cells are arranged in columns or cords passing radially from the central vein of the acinus; the vessels of the lobules run between the spaces. Tease a bit of fresh liver in salt solution; the cells are large, $13-20 \mu$., irregularly polyhedral; protoplasm soft, granular, with one or two distinct nuclei, and frequently fat drops or yellow pigment granules. Twelve or fourteen hours after a heavy meal the cells contain glistening flakes or clumps of glycogen, which stain dark brown with iodine (Heidenhain).

The *connective tissue* forms the capsule and sends a prolongation into the organ at the hilus, the sheath of Glisson, which encloses the artery, portal vein and duct. In the human liver the amount of connective tissue between the lobules is very slight. In the disease called cirrhosis it is greatly increased. Compare sections of normal and cirrhotic human liver. A delicate fibrous tissue surrounds the central vein, and a few fibre cells exist between the columns.

The *blood vessels* must be studied in injected specimens.

The *portal vein* subdivides, and its terminal branches ramify between the lobules, *interlobular* veins. From these vessels a rich plexus of capillaries arises, which penetrates the lobule, passing between the liver cells. In the centre of the

acinus the capillaries unite to form a vessel, *intralobular* or *central* vein, which runs in the axis of the lobule and opens into one of the sublobular veins, and the union of these forms the larger branches of the hepatic veins.

The branches of the *hepatic artery* ramify in the capsule and in Glisson's sheath ; its capillaries supply nutriment to the vessels, ducts and connective tissue, and end in venules which discharge into the *intralobular* veins.

Bile vessels can be demonstrated by injection through hepatic duct, or by injecting indigo-carmin into the veins, when it is eliminated through the bile ducts, which are in this way injected. A successful preparation shows the lobules pervaded with a small meshed net-work of delicate tubules—the bile capillaries. They are very much smaller than the blood capillaries, measuring only 1 to 2 μ ., and are never in contact with them, but run between the surfaces of the liver cells. They appear to possess fine structureless walls. At the periphery of the lobule the capillaries join the interlobular ducts, which unite to form the larger bile vessels, which possess a distinct mucosa, with cylindrical epithelium, numerous mucous glands, a wall of connective tissue, and, in the larger ducts, unstriped muscle fibres.

A transverse section of wall of *gall-bladder* shows the same elements as the larger ducts. The mucosa presents numerous cross ridges.

The *lymphatics* of the liver follow the course of the portal vein, and entering the lobules encircle the capillaries.

The *nerves* can be followed to the interlobular areas, and some observers have traced them into the lobules, but their mode of termination is doubtful.

RESPIRATORY SYSTEM.

With a syringe or large pipette distend lungs of cat or lobe of human lung with $\frac{1}{6}$ % chromic acid solution ; tie the trachea, and suspend in large quantity of same fluid ; change after two days for a $\frac{1}{4}$ % solution, or the chromic acid and spirit solution ; and in 8 or 10 days cut into small pieces and complete the hardening in alcohol.

TRACHEA. In transverse section, observe (1) series of incomplete cartilaginous rings imbedded in a fibrous layer which completes the tube behind, and in this region is strengthened by smooth muscle fibres. (2) Sub-mucous or glandular layer composed of areolar tissue, in which many mucous glands are imbedded, and collections of adipose tissue. Immediately beneath the mucous coat there is a layer of elastic fibres, longitudinally disposed, often, in the human trachea, collected into bundles, and showing clearly to the naked eye. (3) The mucous membrane, composed of a basement membrane, very distinct in man, upon which are several layers of epithelium, the lower cells small, oval or rounded in shape, the most internal columnar and ciliated with interspersed goblet cells.

A section of a *bronchus* shows essentially the same structure, but immediately below the elastic fibres is a continuous ring of unstripped muscle cells, which form a conspicuous and important layer in the bronchi.

LUNG. Prior to imbedding and cutting, soak the bit of lung in the gum or hot wax, in order to fill the air spaces ; otherwise it is difficult to get thin sections.

The lung is composed of a series of *lobules* ; the peripheral ones can be seen mapped out on the surface as irregular polygonal spaces, separated by the interlobular connective tissue septa. With each lobule a terminal bronchus or *bronchiole* stands in relation, forming a narrow tube .20 to .30 mm. in diameter, from which the cartilage rings have disappeared, but

which still retains the muscular and elastic elements, with a layer of low, cubical, ciliated cells. Within the lobule the bronchiole opens into two or three tubular passages or canals, the *alveolar passages*, which have lateral and terminal extensions, the *infundibula*. The walls of the alveolar passages and infundibula are not defined and membranous, as in the bronchiole, but are uniformly beset with the *air cells* or *vesicles*, which open into them by wide orifices, and which form rounded or hemispherical sacculi, from .1 to .4 mm. in diameter. The walls of the alveolar canal, infundibula and air cells are covered with a squamous epithelium placed upon a basement membrane. Numerous elastic fibres exist in the walls, surrounding the orifices of the air cells, and extending over them as a branching network. Muscle fibres are also present in variable numbers, and are increased in certain diseased states. The alveoli are bound together by a delicate connective tissue, in which round and stellate connective tissue corpuscles can be seen. They frequently contain carbon grains, and I have found them in large numbers in specimens of miner's lung (anthracosis). Most of the above details can be followed in good sections of cat's lung. To see the mode of termination of a bronchiole it is, of course, necessary to find one cut in a longitudinal direction. Immediately beneath the epithelial elements of the air cells there is a dense plexus of capillary *blood-vessels*, derived from the branches of the pulmonary artery. So close is the network that the interspaces are narrower than the vessels. In the membrane between adjoining air cells there is only a single plexus. The capillaries of the bronchial arteries are distributed upon the bronchi, the blood-vessels, the connective tissue and pleura, and discharge into the bronchial veins, in some places uniting with the radicals of the pulmonary veins. The *lymphatics* form three sets (Klein), peribronchial, perivascular and sub-pleural, all of which empty into the bronchial lymph glands. Dr. Klein describes *pseudostomata* in the alveolar walls, small, round spaces between the epithelial cells, and in connection with the lymph lacunæ.

Tease a bit of fresh human lung in serum ; observe carefully the elastic fibres, their size, the curved course, and the joining of bundles from contiguous air cells. Boil a bit of lung

in a test tube with 10% caustic potash solution ; examine a teased portion for the elastic elements ; note them particularly, as in the sputa of phthisis, and other lung affections elastic tissue is sometimes met with, and its presence affords important information.

a layer
onchiole
alveolar
e infun-
oula are
but are
en into
pherical
alveolar
quamous
umerous
fices of
ing net-
umbers,
eoli are
und and
requently
umbers in
e above
To see
ecessary
beneath
plexus of
pulmon-
aces are
djoining
s of the
e blood-
into the
ls of the
(in), peri-
pty into
ostomata
epithelial
ve care-
and the
of lung

SKIN AND APPENDAGES.

SKIN. Harden in chromic acid and spirit mixture, changing every second day for a week, and then transfer to alcohol; or in osmic acid, $\frac{1}{4}\%$, for 24 hours, and then in alcohol. It is well to take bits from different regions, finger tips, scalp, ala nasi and scrotum.

In a vertical section observe two layers, the epidermis or external skin and the corium or true skin, beneath which there is the sub-cutaneous areolar and fatty tissue. *Epidermis* is placed upon the corium, and consists essentially of two layers: (1) the rete mucosum or Malpighii, next the corium, composed of strata of cells, the lowest columnar, the middle cubical, and the upper ones somewhat flattened. The cells are large, protoplasm granular, nuclei distinct, and the margins present filaments or prickles, which interlock the cells together (rib or prickle cells of Schultze). The cells of this layer contain the pigment grains upon which the color of individuals depends. (2) The cuticle, horny or corneous layer, consisting of a series of superimposed scale-like cells, which, on section, resemble sinuous fibres, but on maceration in caustic potash, 10%, can be isolated as flattened cells—the so-called epidermic scales. These are best seen by scraping the skin with a knife, and examining the “scurf” so obtained in salt solution. A granular layer, which usually stains deeply, and a clear layer—stratum lucidum—may be seen in the deeper part of the cuticle.

The *corium* forms a dense layer of areolar tissue, arranged in interlacing bundles, among which are elastic fibres, connective tissue cells, fixed and amœboid, and, in some regions, muscle fibres. A thin membrane invests its surface. It presents numerous conical projections, the papillæ, which are ensheathed by the rete mucosum, and contain blood vessels or nerves. They are best seen in section of skin of finger-tip, being most abundant where tactile sensation is most acute. In the lower part, and in the sub-cutaneous tissue, are sebaceous and sweat glands, with hair follicles.

A *sebaceous gland* consists of a group of acini, arranged round a short, wide duct, which usually opens into or in connection with a hair follicle. The cells are cubical or spheroidal, and are usually loaded with fat droplets. A little parasite, *Acarus* or *Demodex folliculorum*, may sometimes be seen in the sebum.

A *sweat* or *sudoriparous gland* is a narrow tube, the end of which, placed in the sub-cutaneous tissue, presents a tuft or coil, the gland proper, which is invested by a loose connective tissue. The secreting cells are cuboidal, and are placed upon a distinct basement membrane. The duct passes vertically through the corium, and in the epidermis pursues a spiral course, opening on the surface by a funnel-shaped orifice.

The *blood-vessels* of the skin are very abundant, forming a lower and upper plexus in the corium ; from the latter, branches pass into many of the papillæ.

The *nerves* of the skin terminate in the tactile corpuscles of the papillæ, in Pacinian corpuscles, and in the rete mucosum by a fine inter-epithelial plexus.

HAIR. Examine a hair of the head ; observe the *cuticle*, consisting of a series of imbricated scales ; the *cortex*, densely packed elongated scales, with different-colored pigment grains interspersed among them ; the *medulla* or pith, not always present, composed of granular polyhedral cells, which sometimes have air bubbles between them. Hairs of the head are cylinders ; those of the beard flattened, and with an oval section.

The hair is placed in a follicle or involution of the corium, and has an epidermic sheath, corresponding to the epidermis ; below it is attached to and grows from the papilla, a conical projection, composed of connective tissue, numerous rounded cells, blood-vessels and non-medullated nerves. Muscle fibres—*erector pili*—are connected with some follicles.

Examine hairs of cat, dog, rat, mouse, horse and ox.

NAILS. Correspond in structure to the skin, and are only modifications of it. The matrix or bed—corium—presents numerous highly vascular papillæ, upon and between which is the rete

mucosum, the cells of which by a gradual process of flattening, become converted into the horny scales, composing the nail proper. These can be isolated after maceration of the nail in 30% caustic potash solution.

GENITO-URINARY SYSTEM.

KIDNEY. Harden bits from organ of man and of cat in the chromic acid and spirit solution, or Müller's fluid (three weeks), and then in alcohol. Neutral chromate of ammonium, 5 %, for two days, then in alcohol to show the rod-epithelium of Heidenhain.

For the epithelium and Henle's loops tease bits of kidney of infant in serum, either fresh or after steeping in Müller's fluid.

The organ consists of a series of complicated tubes—*tubuli uriniferi*—and a rich supply of blood vessels.

Study first a median section of a fresh kidney. Observe (1) the cortical and (2) the medullary or pyramidal portions, the latter being striated and forming cones, which terminate as the papillæ. The cortex is not uniform, but presents definite prolongations from the medulla in the form of bundles of tubules—the *medullary rays*—and in the interspaces between these a double row of small vascular bodies—the Malpighian tufts.

A *uriniferous tubule* begins in the cortex, and after a series of complicated windings opens at the apex of a papilla. It consists of (1) a dilated, flask-shaped extremity—*Bowman's capsule*—a structureless membrane, lined with flattened epithelium. (2) The *convoluted tube*, joined to the capsule by a narrow neck. This portion is wide, and pursues an exceedingly tortuous course. It is lined with polyhedral cells, the outer halves of which present peculiar rod-like structures, resting against the basement membrane—the so-called *rods of Heidenhain*. (3) The tube diminishes rapidly in size, leaves the cortex, and enters the medulla to a variable depth; then, gradually widening, returns to the cortex, forming the *loop of Henle*. The descending limb is very narrow, and is lined with flattened cells, the nuclei of which project and give a sinuous appearance to the lumen. The ascending limb is much wider, and its epithelium is essentially the same as in the convoluted tube. (4) The tube again becomes convoluted, *intercalated portion*, and eventually terminates in (5) a *collecting tubule* of medullary ray, which,

small at first, passes into the pyramid, gets larger, and uniting with others, forms one of the large (6) *discharging* tubes. The epithelium of these varies somewhat in different regions; in the collecting tubules it approaches the cylindrical form; in the discharging tubes the cells are typical cylinders.

To see the general arrangement of the convoluted and straight tubes, study large sections of cat's kidney under low power. Cross sections of the straight tubes show very well the different size of the tubules and similar sections of the cortex show the medullary rays in bundles among the convoluted tubes. To isolate the tubes, soak a bit, the size of a pea, in pure hydrochloric acid for twelve hours, and then in water for a day; tease in osmic acid, 1%, and mount in Farrant's solution (Stirling).

Blood-vessels. A peculiar and beautiful arrangement of the blood-vessels exists, the details of which can be followed in well-injected specimens. The medium-sized arteries run on the surface of the pyramids, and send branches up into the cortex and down into the medulla. The former pass between the medullary rays and give off little branches, each of which penetrates a capsule—*vas afferens*—and breaks up into a coil of capillaries, the *Malpighian tuft* or *glomerulus*, from which a small vein arises, emerges from the capsule—*vas efferens*—near the afferent artery, and then forms a dense network of capillaries about the convoluted tubes, from which a vein arises. The *glomerulus* has a delicate coating of flat epithelial cells. From the arteries, at the bases of pyramids, other branches penetrate the medulla—*arterioli rectæ*—and break up into capillaries about the straight tubules.

The *connective tissue* of the kidney is scanty, particularly in the cortex. In teased sections spindle-shaped corpuscles are not uncommon, and in cross-sections of the pyramids a nucleated connective tissue is seen separating the tubules. A delicate layer, strongly developed in some cases of disease, exists about the Malpighian capsules.

URETER AND BLADDER. Distend separately with chromic acid and spirit solution; place in same mixture for several days, and then in alcohol.

Ureter. A section shows an external fibrous sheath ; two muscle layers, an internal longitudinal and an external circular ; a mucous coat, with epithelium same as bladder.

Bladder has essentially the same structure, but a serous membrane covers it in part, and the muscular coat consists of numerous bundles of interlacing fibres, described as occurring in three layers—circular, longitudinal and oblique. The *epithelium* is important, and can be studied in sections or in fresh teased specimens. That of the ureter and pelvis of kidney presents the same appearance ; it is of the variety known as transitional. (See Epithelium).

PROSTATE. Made up of saccular acini, lined with cylindrical epithelium and surrounded with a large amount of connective tissue and muscle fibres.

TESTIS. Organ of dog, rabbit or pig, sliced in several directions, and hardened in chromic acid and spirit solution, and after a week in alcohol.

To isolate the tubes, macerate, at about 30° C., in hydrochloric acid (one of acid to two of water) for 48 hours, and separate carefully in water.

Section of gland shows a fibrous capsule, *tunica albuginea*, which sends septa into the substance, dividing it into a number of lobules, filled with the *seminal tubes*, which divide and subdivide, and are much folded. Each tube consists of (1) a *membrana propria*, composed of flattened epitheloid cells. (2) The seminal cells, arranged in several layers, the outermost rounded and faintly granular, the inner polyhedral, granular and present numerous developing spermatozoa—hence the term spermatoblasts is given to them. The mode of their development in the cells is still disputed, but it appears that the nuclei divide into a number of portions, each of which forms a head, while the tail results from the transformation of the granular protoplasm of the cell (Fleming. *Archiv f. Micros. Anat.*, Bd. XVIII.) In the tubes they can be seen in groups, heads together and the tails forming brush-like extensions towards the lumen.

Spermatozoa. Obtain from *vesiculæ seminales* or testicle of man, or, in living state, by squeezing penis of dog, and at same

time placing slide against the glans. Can be mounted dry, or in glycerine to which a few drops of alcohol have been added.

Observe (1) head, which is pear-shaped, flattened, and presents an anterior dark and a posterior lighter segment. (2) The tail, consisting of an anterior thicker portion—in spermatozoa of some animals very distinct, and known as the middle part or body—and a long tapering thread, the tail proper. A delicate vibratile filament, often spirally arranged, exists in the tail or is attached to it by a thin membrane, and it is by means of this that the active movements are effected. (Eimer, Jensen, Gibbes.)

OVARY. Harden ovary of cat or dog in chromic acid and spirit solution. If human ovary, make several cuts into it. It is best to stain the sections in carmine. They must be handled very carefully, as the ova are liable to fall out of the larger follicles.

The organ is made up of (1) an external *epithelial coating* of low columnar cells. (2) The *parenchyma*, composed of dense connective tissue, with some elastic and muscular elements. (3) The *Graafian follicles*, situated in the outer or cortical part of the stroma. They vary in size from a pin's head to a pea, and in a large one the following parts can be seen: (*a*) fibrous coating, continuous with the stroma of the gland; (*b*) a basement membrane, lined by (*c*) several layers of granular cells—the *membrana granulosa*. The ovum is usually attached to one side of the follicle, and is surrounded by (*d*) the *discus proligerous*, composed of irregular granular cells, which completely invest the ovum; (*e*) the *liquor folliculi*, an albuminous fluid, which fills the follicle. The *ovum* is a spherical body, consisting of the *vitellus* or *yolk*, with a vesicular nucleus, the *germinal vesicle*, which contains a nucleolus, the *germinal spot*. Surrounding the vitellus is the *zona pellucida*, a finely striated cell wall, and on the outside of it a layer of cells—the epithelium of the germ.

In the sections numerous small *unripe* follicles can be seen near the surface, containing distinct ova but no follicular fluid.

Corpus luteum. After the rupture of the mature follicle and the discharge of the ovum, certain changes go on in the sac,

which result in the formation of a structure known as the *corpus luteum*. A section of a fully developed one shows (1) an external convoluted wall of a yellow color, composed of irregular cells, with yellow pigment grains; sometimes large multinuclear cells are seen. The precise mode of development of this distinctive layer is still in dispute, whether from *granulosa* remnants, cells of the stroma, or migrated white blood corpuscles (2) A central mass, which results from the transformation of the blood effused after the rupture, and which consists of a vascular tissue (organized clot), with a few cells. Color is variable, often light reddish brown in centre and a pale, peripheral part. Hæmatoidin grains and crystals are numerous, and are easily obtained from ovary of cow. Occasionally a central cavity, containing serum, is found. The corpus luteum which forms after menstruation reaches its full development in about three weeks—*corpus luteum of menstruation*; when impregnation takes place the corpus luteum grows much larger, reaches its full size in about three months—*corpus luteum of pregnancy*. Retrograde changes then go on, and, in the former case in a few weeks, in the latter in four or five months, reduce the corpus to the condition of a white cicatrix, often with a dark centre. Frequently in sections deeply placed follicles are seen, with rigid, white, puckered walls. These are the *false corpora lutea* (Dalton), which result from a saccular degeneration of the follicles, and *the term should not be, as it sometimes is, applied to the corpus luteum of menstruation.*

FALLOPIAN TUBE. Prepare in same way as ovary. In transverse section, (1) serous coat; (2) muscular, double layer, internal circular, the thicker of the two; (3) the mucous membrane, in longitudinal folds; epithelium is cylindrical and ciliated, direction of the current is towards the uterus.

UTERUS. Prepare in same way as ovary, or in case of small animals the solution may be injected into it, and the vagina tied. The organ should be obtained as fresh as possible.

It presents for study (1) serous coat. (2) A very thick musculature, disposed in several layers, the fibres being of the unstriped variety. (3) The mucosa, a thin lining, closely united to the

muscular coat, which presents (*a*) a uniform covering of cylindrical ciliated cells, (*b*) a stroma of spindle-shaped cells, and (*c*) tubular glands, often tortuous or branched, and lined throughout with columnar ciliated epithelium.

Study with great care teased preparations of fresh mucosa in serum ; sketch and observe the various sorts of cells. Isolate, by teasing, the muscle cells (*a*) of unimpregnated (*b*) of pregnant uterus. This is greatly facilitated by soaking a portion of the tissue in 1% bichrom. solution. The cells are fusiform or flattened, in the unimpregnated organ about .045 mm. in length, nucleus single, rod-shaped. The fibres are held together by a cement substance of connective tissue, in which small cells are to be seen. In the organ at term, or shortly after delivery, the muscle cells are greatly enlarged, measure .660 mm. in length, and look altogether broader and bigger.

VAGINA. Study epithelium ; large squamous cells, often folded. In sections muscular and fibrous layers can be seen outside of the mucosa.

MAMMARY GLAND. Harden in chromic and spirit solution, then in alcohol, and stain with logwood.

It consists of a series of acinous or racemose glands, united by a connective tissue framework, which separates the lobules and encloses the vessels and ducts. Each lobule consists of a group of acini, arranged round a terminal duct. The acini or gland vesicles are rounded or polyhedral in shape, and present a basement membrane lined by short columnar cells, which, in the functionally active gland, may be seen to contain milk globules. It is probable that the cells give exit to the oil globules without undergoing destruction. The gland ducts are lined with cuboidal cells ; near the nipple the large galactophorus ducts present saccular dilatations.

EYE.

Cornea. Prepare in Müller's fluid and alcohol; stain in carmine or logwood. For corneal corpuscles, soak in gold chloride solution, $\frac{1}{2}$ %, for an hour; then in acidulated water, and mount in glycerine. For lymph spaces, pencil with solid stick of silver nitrate; mount in glycerine.

In section, observe: (1) Anterior epithelium, stratified, many of the cells "ribbed." (2) Bowman's membrane or anterior elastic lamina, a clear homogeneous layer. (3) The substantia propria, made up of lamellæ of fibrous tissue, separated by an albuminous cement, in which are the lymph spaces and corpuscles. (4) The posterior elastic lamina or Descemet's membrane, a structureless, transparent layer, upon which there is placed (5) the posterior epithelium, a single layer of cuboidal cells.

The lymph canaliculi are flattened stellate spaces, which anastomose with each other. They contain the fixed corneal corpuscles, which are flat cell plates, with pointed processes. Amœboid cells are also found in the spaces.

The delicate nerve fibres end in a sub-epithelial and an intra-epithelial plexus (Klein).

Sclerotic. Composed of interlacing bundles of fibrous tissue, with a few elastic fibres.

Lens. Composed of elongated fibres, forming broad, flat bands, hexagonal on section. They can be most readily studied in the eye of any large fish; boil the lens for a few minutes, strip off a few fibres, and mount in glycerine. They present numerous serrations, which interlock the contiguous fibres.

Choroid. This layer consists of a connective tissue parenchyma, a few elastic fibres, pigment cells, and numerous blood-vessels.

Tease bit of fresh choroid of pig's eye in serum for the branched pigment cells.

Study the relation of the parts at the corneo-sclerotic junction in a good horizontal section. Notice: (1) The transition of the cornea into the sclera; a small aperture at the junction, the canal of Schlemm. (2) The choroid, lining the sclera behind and presenting folds, the ciliary processes; in front it is continuous with the iris. (3) The ciliary muscle, consisting of a radial and a circular set of fibres, attached in front at the corneo-sclerotic junction, and passing back to be inserted into the choroid and its ciliary processes.

The *iris* resembles the choroid in structure, but has a double set of smooth muscle fibres; the *sphincter*, forming a ring near the margin of the pupil, and the *dilator*, the fibres of which pass radially towards the periphery.

Retina. Posterior half of eye of pig or fresh human eye in Müller's fluid for a week, and then in alcohol.

In a successful section observe following layers:—

(1.) Internal limiting membrane, next the vitreous.

(2.) Layer of nerve fibres, non-medullated.

(3.) Ganglion-cell layer, usually but one row. An axis-cylinder enters the inner side, and each cell sends off processes into the next layer.

(4.) Inner molecular layer, composed of a homogeneous substance, with numerous little spaces in it.

(5.) Inner nuclear layer, made up of oval nerve cells, with distinct nuclei and a process from either end. There are also some unbranched cells.

(6.) Outer molecular layer, similar to but much thinner than the inner.

(7.) Outer nuclear layer, consisting of oval cells, which are connected by fibres with the rods and cones.

(8.) External limiting membrane, a clear, well-defined line at the base of the rods and cones.

(9.) Layer of rods and cones. Rods are cylindrical, and consist of an inner and outer part, the latter being transversely striated. The cones are bottle-shaped, and consist of an inner cone, and an outer cylinder, like that of a rod, but not of equal height.

(10.) Pigment layer, which receives the ends of the rods and cones, forms a single stratum of flattened hexagonal cells.

Layers 7 and 9 constitute the *neuro-epithelium* (Schwalbe), in which the optic nerve fibres terminate.

A connective tissue framework supports these layers, chiefly as the fibres of Müller, which arise from the internal limiting membrane, and pass through the whole thickness to the external membrane.

EAR.

External meatus is lined by an extension of skin, which presents numerous ceruminous glands, resembling the sweat glands in structure.

Membrana tympani. Three layers: *External* is a layer of squamous epithelium; *middle*, composed of fasciculi of fusiform fibres, in several layers, with blood vessels, lymph channels and nerves; *internal*, a layer of flat epithelial cells.

Tympanum. Mucosa consists of a basement of connective tissue, upon which is placed an epithelium, which, in places, is columnar and ciliated, but on the roof, the membrana and on the ossicula is squamous.

Eustachian tube. Mucosa is lined by a layer of columnar ciliated cells.

Cochlea. Remove organs from guinea-pig, put in Müller's fluid for ten days, then in saturated picric acid until softened. Transfer to weak spirit, and in twenty-four hours to strong spirit (Schäfer).

The cochlea is a spiral tube, taking two and a-half turns round a central axis—the modiolus. The canal is divided by a thin partition, partly osseous, partly membranous—the *lamina spiralis*, into an upper part, the *scala vestibuli*, and a lower portion, the *scala tympani*. From the middle of the spiral lamina a thin membrane passes to the outer wall of the scala vestibuli, cutting off a narrow triangle, known as the *ductus cochleæ*.

The organ of Corti, a peculiar body in which the cochlear nerve terminates, is placed in this duct, being situated upon the basilar membrane—the membranous portion of the lamina spiralis.

These three cochlear canals are lined with squamous epithelium. The organ of Corti forms a complicated epithelial structure, projecting as a small arch on the floor of the ductus cochleæ.

It consists of an inner and an outer set of rods or pillars, inclined towards each other, the heads interlocking and leaving a little channel beneath. In connection with these rods are epithelial cells with hair-like prolongations, four rows on the outer side of the outer pillar, one on the inner side of the inner. Beyond these the epithelium is cylindrical, and then cuboidal. The nerves have been traced to the inner and outer hair cells.

Membranous semi-circular canals consist of (1) an external connective tissue layer; (2) a middle tunica propria; (3) an internal pavement epithelium.

In the *ampullæ* the epithelium presents a number of columnar supporting cells, between which are placed fusiform cells provided with stiff cilia—*auditory hairs*. These cells appear to be in direct connection with the terminal filaments of the vestibular nerve.

NOSE.

Three regions : Vestibulum nasi, pars respiratoria, and pars olfactoria.

The *vestibulum* comprises the part just within the nostrils, and surrounded by the cartilages. The membrane covering it is an extension of the skin, which gradually merges into the mucous layer. The epithelium is squamous.

The *respiratory portion* comprises the greater part of the fossæ, except the upper region. The mucosa, known as the Schneiderian membrane, is composed of ciliated epithelium placed upon a connective tissue stratum, which forms a periosteum for the nasal bones. In the fossæ it is thick, and presents mucous glands, with numerous blood-vessels, arranged, according to some writers, as an erectile tissue. In the sinuses it is thinner.

The *olfactory portion*, confined to the roof, upper part of the septum and the superior turbinated bones, has a light yellow-brown color. The membrane is made up of a connective tissue matrix, covered with two sorts of epithelium, one the *olfactory cells*, elongated structures, with fine cilia on the surface, which are connected below with terminal filaments of the olfactory nerve. In mammals the cilia are absent. The other variety are ordinary columnar cells. These cells are best studied in the newt or frog, after immersion of the head, with the nostrils slit up, in Müller's fluid. Numerous pigment granules, and some pigment cells exist in this part. Bowman's glands, tubular in structure, are seen throughout the thickness of the mucosa.

INDEX.

	PAGE
Acarus folliculorum.....	43
Accessories—Microscopic.....	xvi.
Achorion Schönlini.....	4
Adipose tissue.....	14
Adjustments.....	viii.
Adenoid tissue.....	13
Air bubbles.....	1
Air cells.....	40
Alcohol.....	xi.
Alimentary canal.....	31
Alveolar passages.....	40
Amœba.....	2
Ammonium chromate.....	xi.
Ampullæ.....	55
Aniline dyes.....	xiv.
Areolar tissue.....	13
Arteries.....	25
Arteriolæ rectæ.....	46
Auditory hairs.....	55
Auerbach's plexus.....	36
Bacteria.....	4
Bacillus.....	5
Bichromate of potash.....	xi.
Bichromate of ammonia.....	xi.
Bile vessels.....	38
Bladder.....	47
Blood corpuscles—Man.....	6
“ “ —Other animals.....	9
“ “ —Nucleated.....	9, 17
Blood crystals.....	9
“ Counting.....	9
Blood vessels.....	25
Bone.....	16
Bowman's capsule.....	45
“ membrane.....	51
“ glands.....	56
“ disks.....	19
Bronchus.....	39

	PAGE
Brownian movement.....	1
Brunner's glands.....	35
Camera lucida.....	ix.
Canaliculi of bone.....	16
" Serous.....	27
" ".....	xvi.
Canada Balsam.....	25
Capillaries.....	xiii.
Carmine fluids.....	15
Cartilage.....	2
Cells.....	3
Cell multiplication.....	17
Cells with red-blood corpuscles.....	23
Central canal.....	23
Cerebrum.....	24
Cerebellum.....	17
Charcot's crystals.....	51
Choroid.....	xi.
Chromic acid.....	xi.
Chr. acid and spirit.....	1
Chyle.....	52
Ciliary muscle.....	26
Circulation.....	23
Clarke's column.....	54
Cochlea.....	13
Connective tissues.....	51
Cornea.....	52
Corneo-sclerotic junction.....	54
Corti, organ of.....	48
Corpus luteum.....	42
Corium.....	1
Cotton fibres.....	6
Crenation.....	31
Crusta petrosa.....	xii.
Cutting sections.....	3
Cyclosis.....	31
Czermack's spaces.....	xi.
Dammar.....	43
Demodex folliculorum.....	31
Dentine.....	51
Descemet's membrane.....	xii.
Dissociating fluids.....	ix.
Drawing.....	54
Ductus cochleæ.....	1
Dust.....	1

PAGE		PAGE
I	Ear	54
35	Elastic tissue	14
ix.	Elastic fibres of lung	40
16	Elastic cartilage	15
27	Enamel	31
xvi.	End bulbs	21
25	Endoneurium,	21
xiii.	Endothelium	11
15	Epidermis	42
2	Epithelium, squamous,	11
3	" glandular	11
17	" columnar	12
23	" ciliated.	12
23	" transitional	12
24	Erector pili	43
17	Eustachian tube	54
51	Eye	61
xi.	Eye-piece	viii.
xi.		
I	Fallopian tube	49
52	False corpora lutea	49
26	Farrant's solution	xvi.
23	Fibrin fibrils	8
54	Fibrous tissue	14
13	Fibro-cartilage	15
51	Fungi	4
52		
54	Genito-urinary system	45
48	Glomerulus	46
42	Gold chloride	xv.
I	Gold size	xvi.
6	Glycerine	xvi.
31	Glycerine jelly	xvi.
xii.	Graafian follicle	48
3	Granules	I
31		
xi.	Hair	43
43	Hardening fluids	xi.
31	Haversian canals	15
51	Hæmin	10
xii.	Hæmatoidin	10
ix.	Hæmoglobin	9
54	Hæmatoxylin'	xiv.
I	Heart, muscle fibres	19
	Heidenhain's rods	45

	PAGE
Henle's loop.....	45
Hepatic artery.....	38
Illumination.....	viii.
Imbedding mixtures.....	xii.
Imbedding.....	xii.
Immersion lens.....	viii.
Infundibula.....	40
Indifferent fluids.....	x.
Intestine, small.....	34
" large.....	36
Interlobular veins.....	37
Iodized serum.....	x.
Iris.....	52
Kidney.....	45
Krause's membrane.....	19
Lacunæ.....	15
Lamina spiralis.....	54
Lens.....	51
Leucocyte.....	7
Lieberkühn's glands.....	35
Linen fibres.....	i
Liver.....	37
Logwood.....	xiv.
Lung.....	39
Lymph vessels.....	27
" glands.....	27
" sacs.....	27
Magenta.....	xiv.
Malpighian corpuscles.....	28
" tufts.....	46
Mammary gland.....	50
Marrow.....	17
Meatus externus.....	54
Meissner's plexus.....	30
Membrana tympani.....	54
Methyl-aniline.....	xiv.
Micrococci.....	4
Microcytes.....	6
Microscope.....	vii.
Microtomes.....	xiii.
Microsporion furfur.....	4
Milk.....	1

PAGE		PAGE
45	Motorial end-plates.....	21
38	Moulds.....	4
	Mounting.....	xv.
viii.	Mucoid tissue.....	12
xii.	Müller's fluid.....	xi.
xii.	Muscular tissue.....	18
viii.	Myeloplaques.....	17
40		
x.	Nails.....	43
34	Nerve cells.....	21
36	Nerve fibres.....	20
37	Nerve endings.....	21
x.	Neuroglia.....	14, 22
52	Neurolemma.....	21
	Neumann's sheath.....	31
45	Objective.....	vii.
19	Oil drops.....	1
	Olfactory cells.....	56
15	Oesophagus.....	33
54	Osmic acid.....	xii, xv.
51	Ovary.....	48
7		
35	Pacinian corpuscles.....	21
i	Pancreas.....	36
37	Papillæ, of finger.....	42
xiv.	“ of tongue.....	32
39	Penicillium glaucum.....	
27	Perineurium.....	21
27	Perivascular lymph space.....	26
27	Peyer's glands.....	35
	“ patches.....	35
xiv.	Picric acid.....	xii.
28	Picro-carminé.....	xiv.
46	Pigment tissue.....	15
50	Portal vein.....	37
17	Prostate.....	47
54	Protoplasm.....	2
30	Pulp.....	31
54	Purkinje's cells.....	24
xiv.		
4	Ranvier, node of.....	20
6	Respiratory system.....	39
vii.	Retina.....	52
xiii.	Rete mucosum.....	42
4	“ Malpighii.....	24
1	Rods and cones.....	52

	PAGE
Saccharomycetes.....	4
Salivary glands.....	32
Salt solution.....	x.
Sarcous elements.....	19
Scala vestibuli.....	
" tympani.....	
Schäfer's rods.....	
Schlemm's canal.....	52
Schizomycetes.....	4
Schneiderian membrane.....	56
Schwann's sheath.....	20
Schultze's granules.....	8
Sclerotic.....	51
Sebaceous gland.....	43
Semi-circular canals.....	55
Serum.....	x.
Sharpey's fibres.....	16
Silver nitrate.....	xiv.
Skin.....	42
Small intestine.....	34
Softening solutions.....	xii.
Spermatozoa.....	47
Spinal cord.....	22
Spirillum.....	5
Spleen.....	28
Staining fluids.....	xiii.
Starch grains.....	1
Stomata.....	27
Stomach.....	33
Substantia gelatinosa.....	23
Sudoriparous glands.....	43
Supra-renal capsules.....	29
Sweat glands.....	43
Tactile corpuscles.....	21
Taste goblets.....	32
Teasing.....	xi.
Testis.....	47
Thymus.....	29
Thyroid.....	29
Tongue.....	
Tonsils.....	32
Torula.....	4
Trachea.....	39
Trichophyton tonsuraus.....	4

PAGE		PAGE
..... 4	Tubuli uriniferi.....	45
..... 32	Tympanum	54
..... x.	Ureter	47
..... 19	Uterus	49
.....	Vacuolation	3
.....	Vagina.....	50
..... 52	Vegetable cell.....	2
..... 4	Veins.....	25
..... 56	Vibrio	5
..... 20	White-blood corpuscles.....	7
..... 8	White fibrous tissue.....	14
..... 51	Woody fibres.....	1
..... 43	Woollen fibres.....	1
..... 55	Yolk of egg.....	1
..... x.		
..... 16		
..... xiv.		
..... 42		
..... 34		
..... xii.		
..... 47		
..... 22		
..... 5		
..... 28		
..... xiii.		
..... 1		
..... 27		
..... 33		
..... 23		
..... 43		
..... 29		
..... 43		
.....		
..... 21		
..... 32		
..... xi.		
..... 47		
..... 29		
..... 29		
.....		
..... 32		
..... 4		
..... 39		
..... 4		

